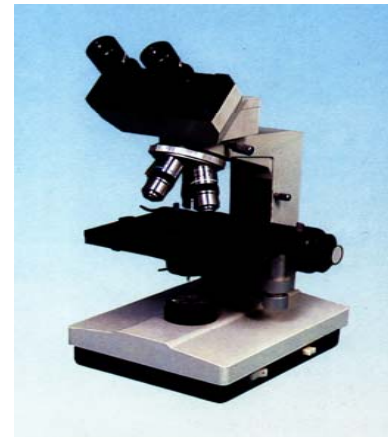


# Experimental Courseware of Histology and Embryology



**Chapter 1 Introduction and Cell**

**Chapter 2 Epithelial tissue**

**Chapter 3 Connective Tissue**

**Chapter 4 Blood**

**Chapter 5 Cartilage and Bone**

**Chapter 6 Muscle Tissue**

**Chapter 7 Nerve Tissue**

**Chapter 8 Circulatory System**

**Chapter 9 Immune System**

**Chapter 10 Skin**

**Chapter 11 Digestive Tract**

**Chapter 12 Digestive Gland**

**[Chapter 13 Respiratory System](#)**

**Chapter 14 Urinary System**

**Chapter 15 Endocrine System**

**Chapter 16 Sense Organs**

**Chapter 17 Male Reproduction**

**Chapter 18 Female Reproduction**

**Chapter 19 Embryology 1**

**Chapter 20 Embryology 2**

# Chapter 13 Respiratory System

## I Slides

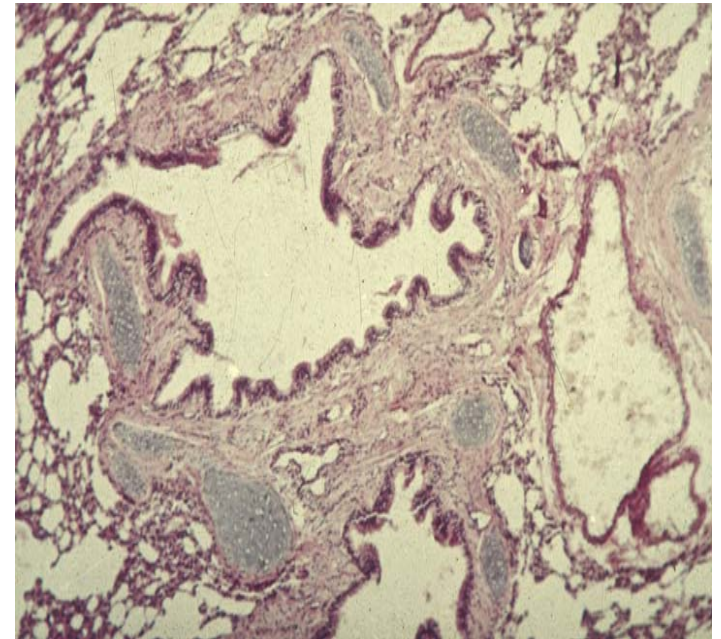
### II Sections

NO 79 trachea.

NO.80 lung

III EM photos: 59~61

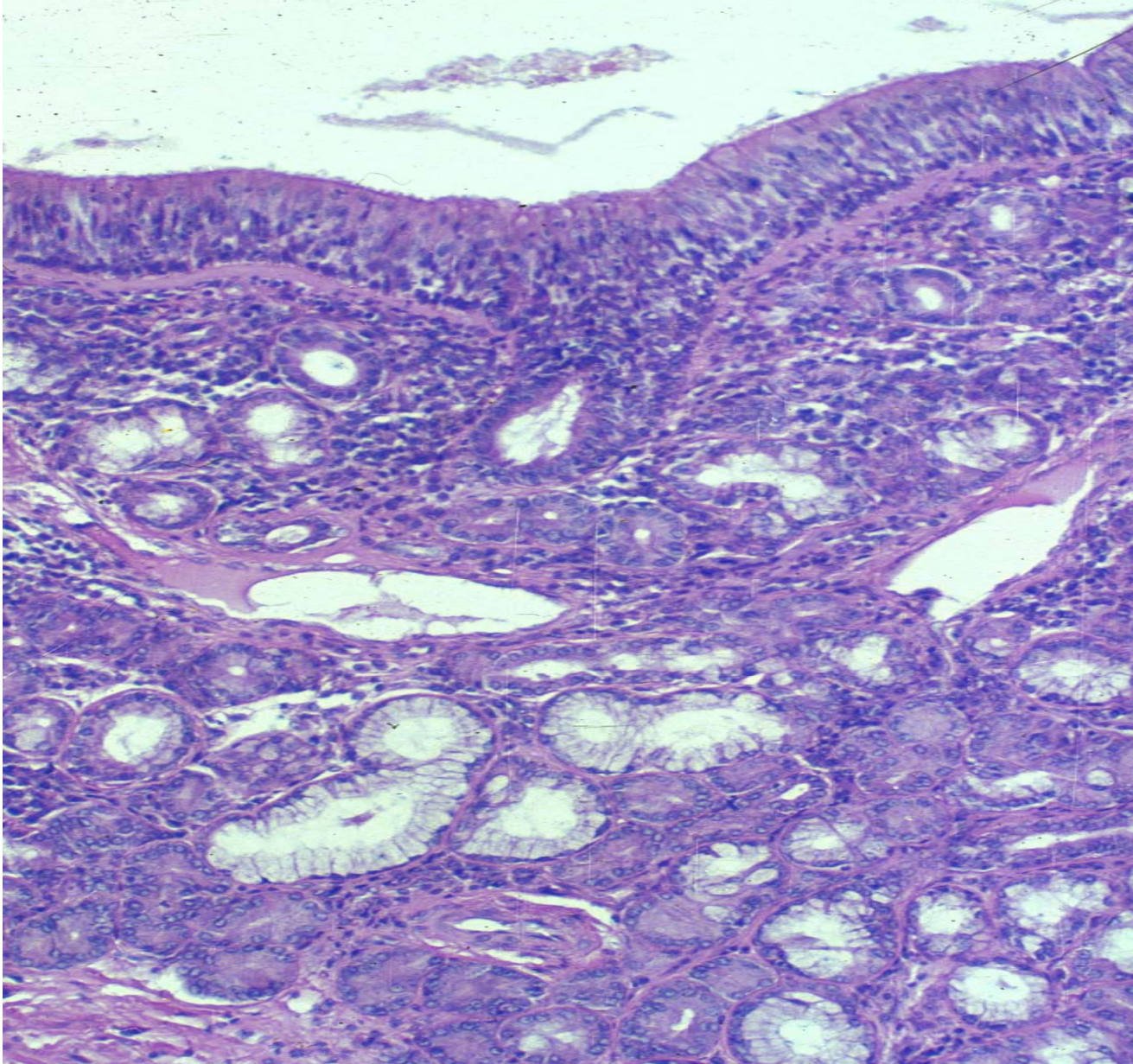
### IV Summary



# Summary

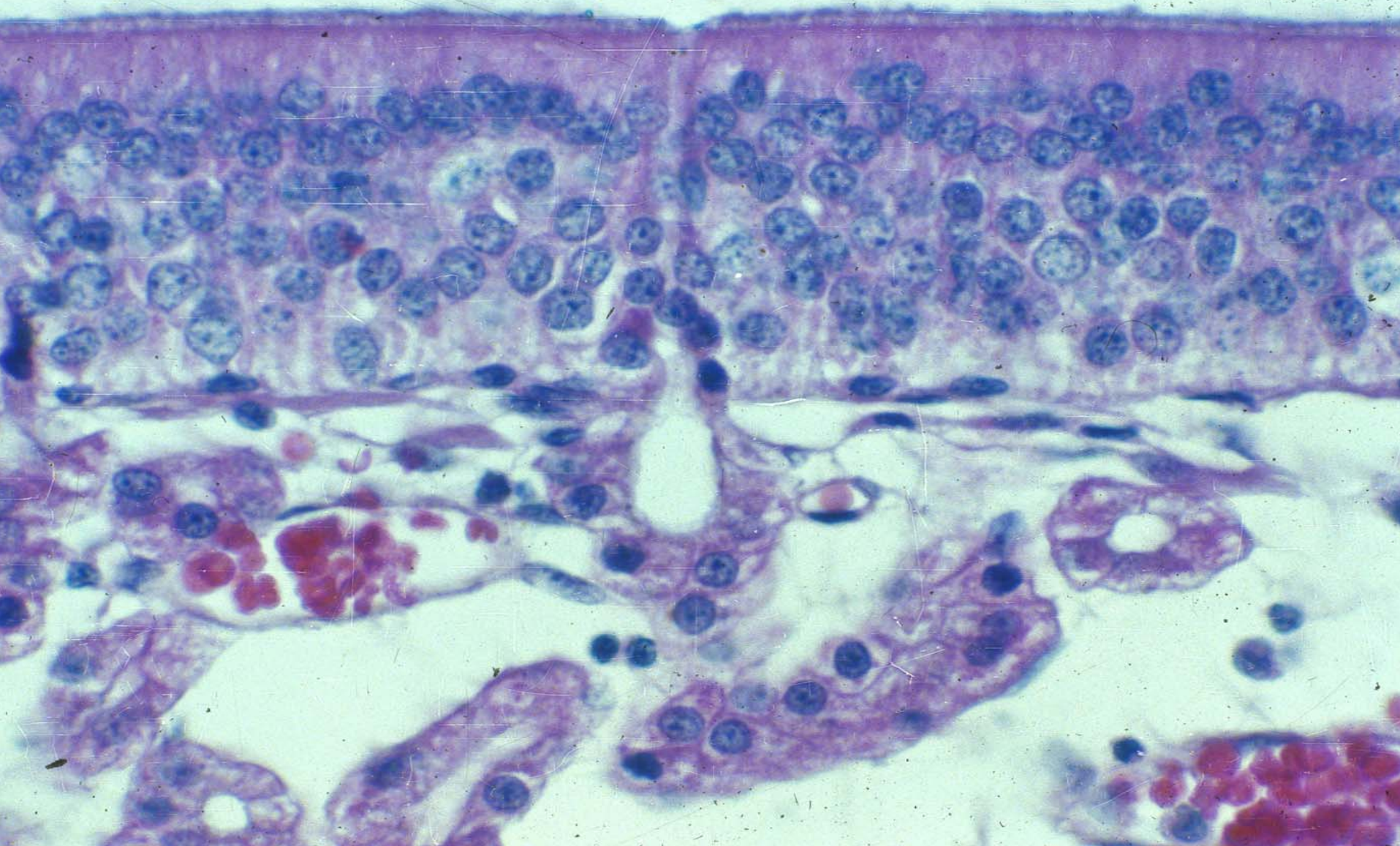
1. The structure of trachea and bronchi.
2. The structure of lung, ultrastructure of alveoli.





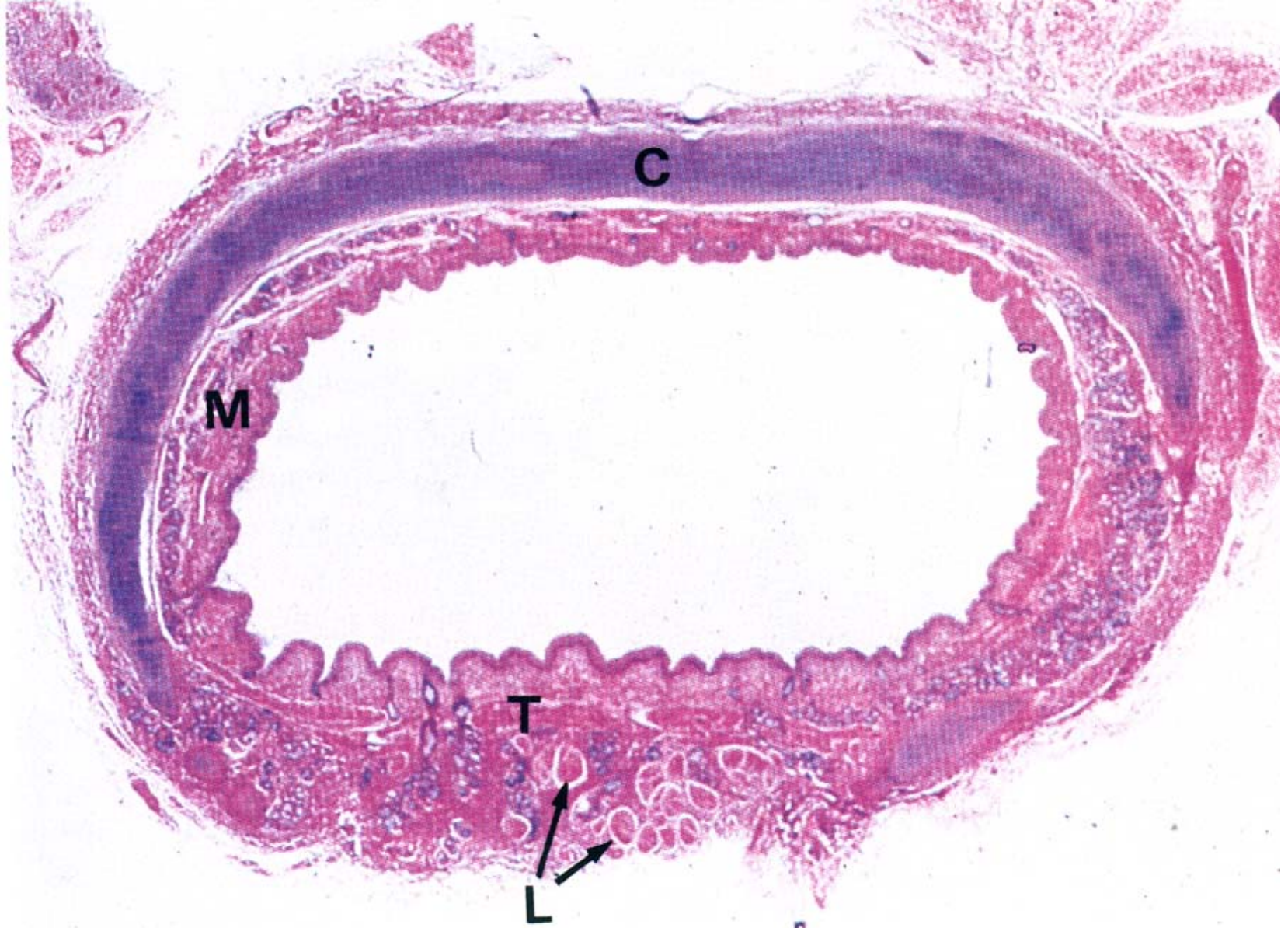
Respiratory region





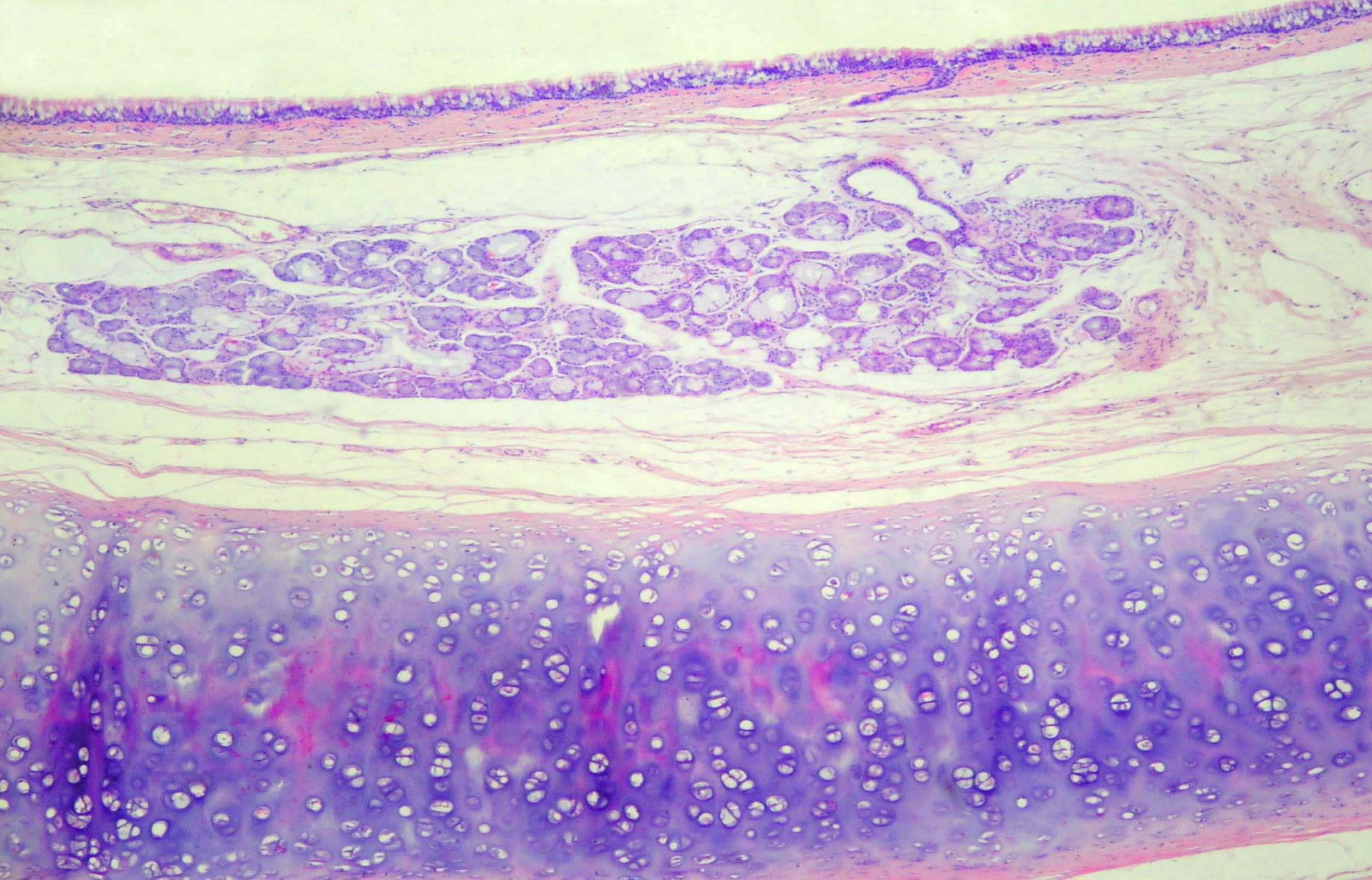
Olfactory region





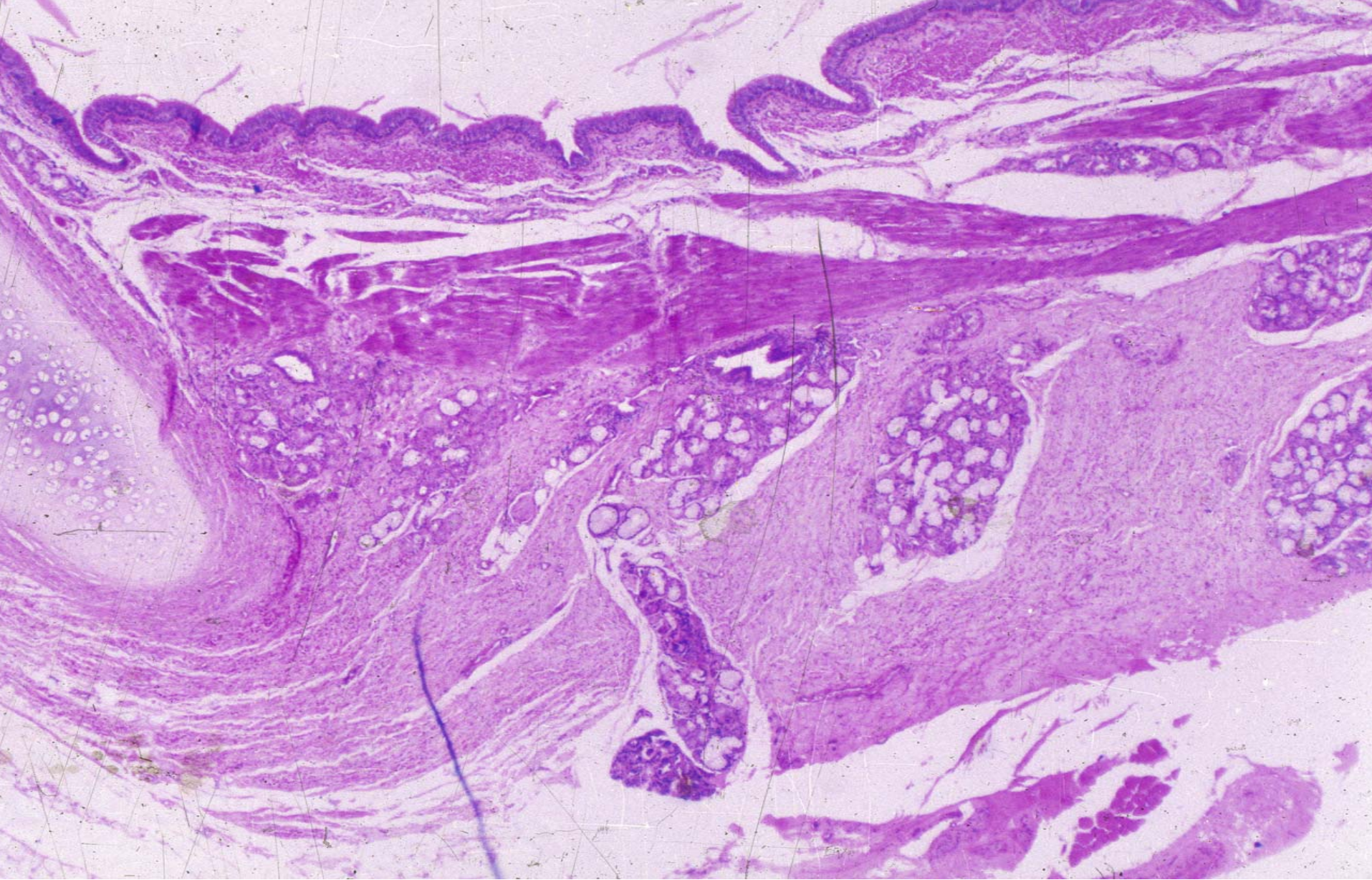
trachea





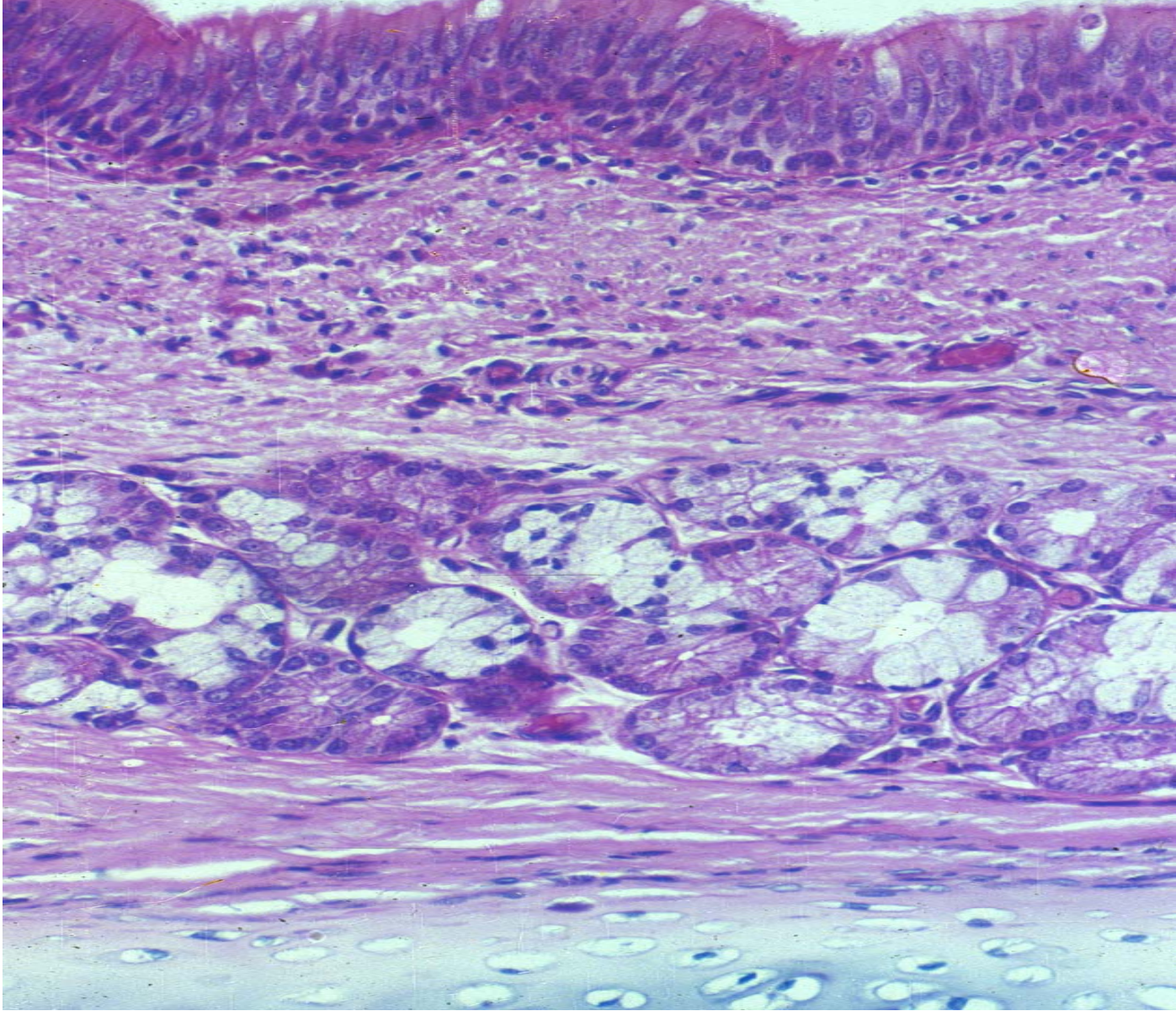
trachea





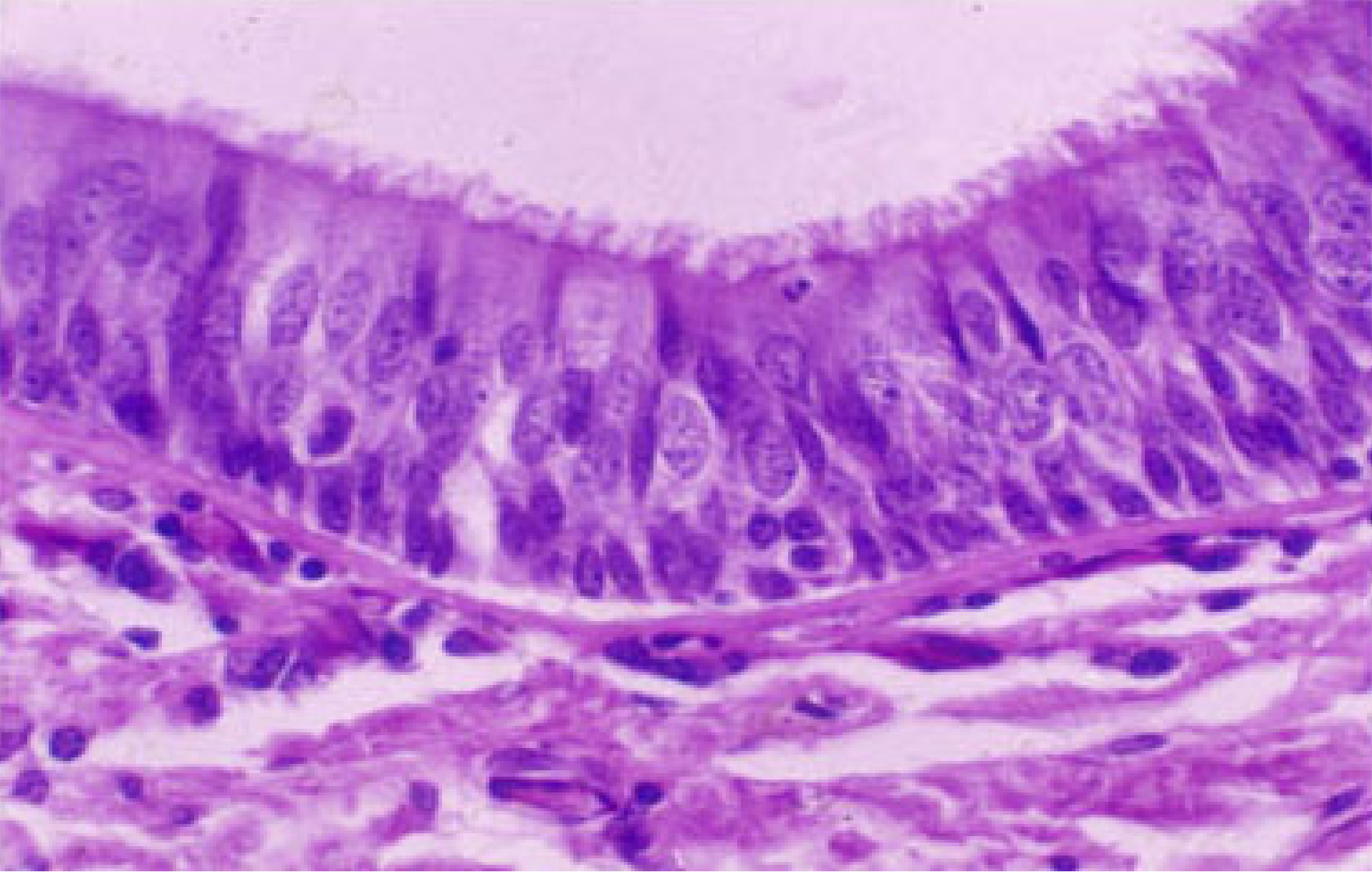
trachea





trachea



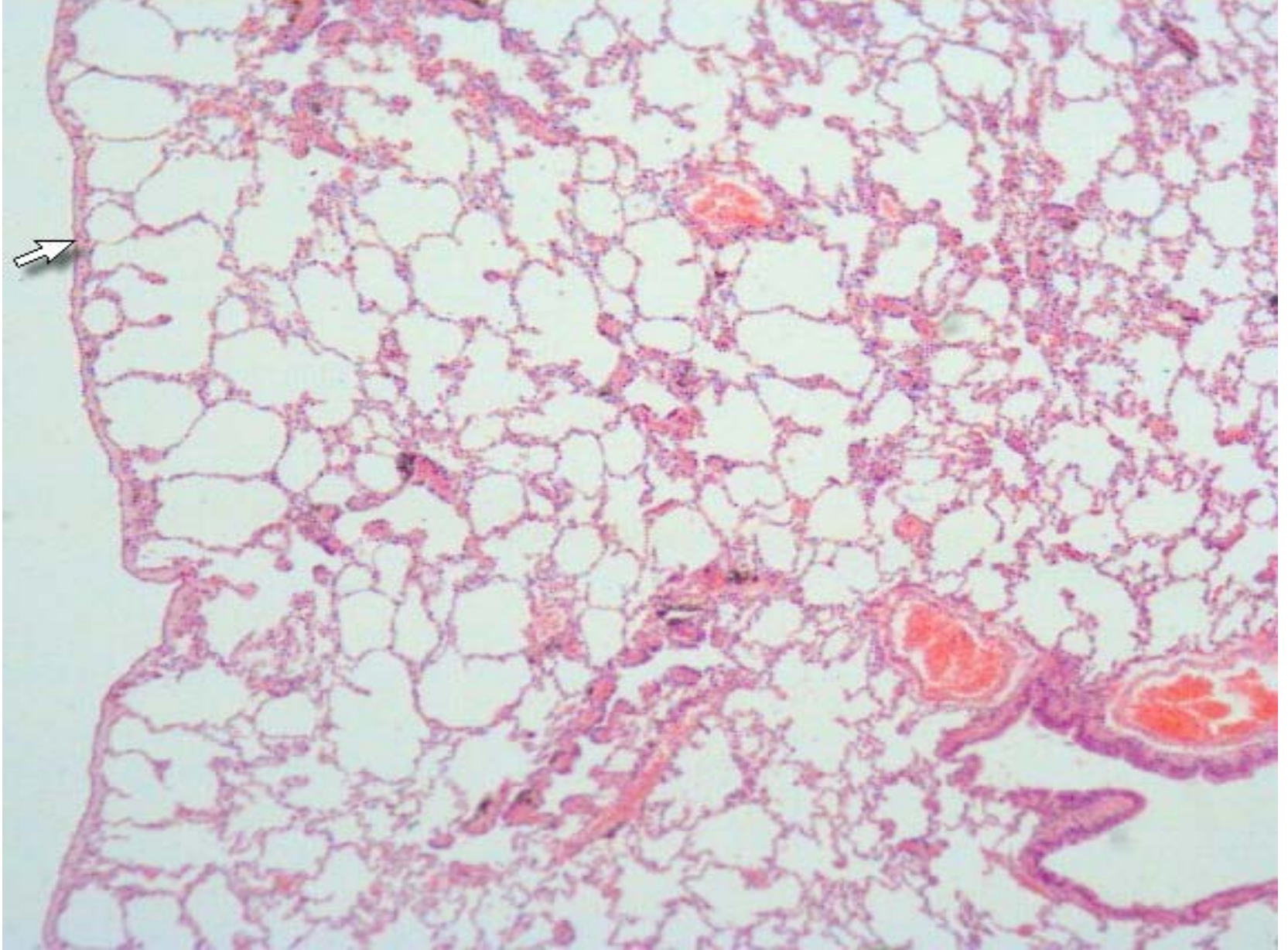


Pseudostriated ciliated columnar epithelium



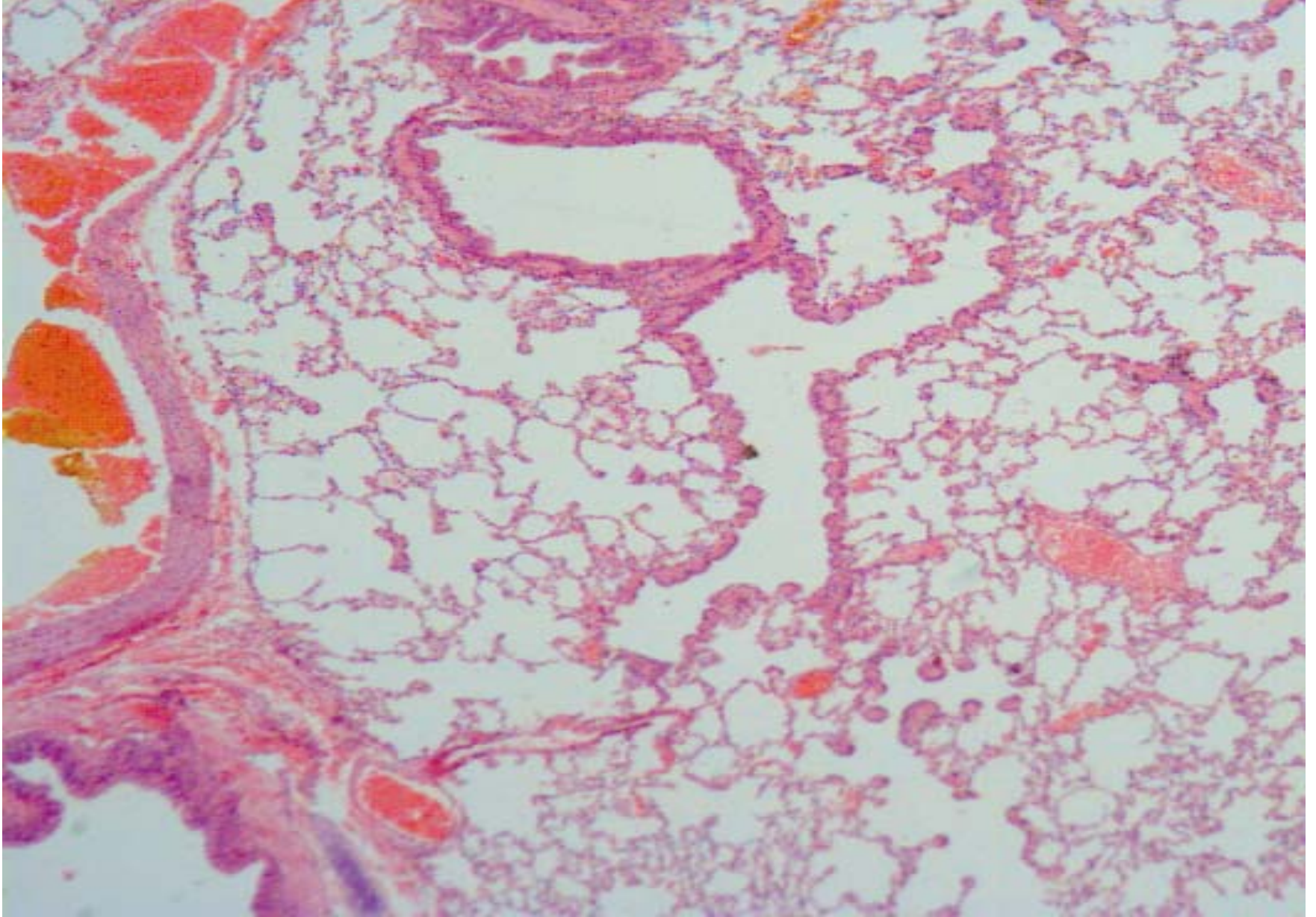
Surface of trachea





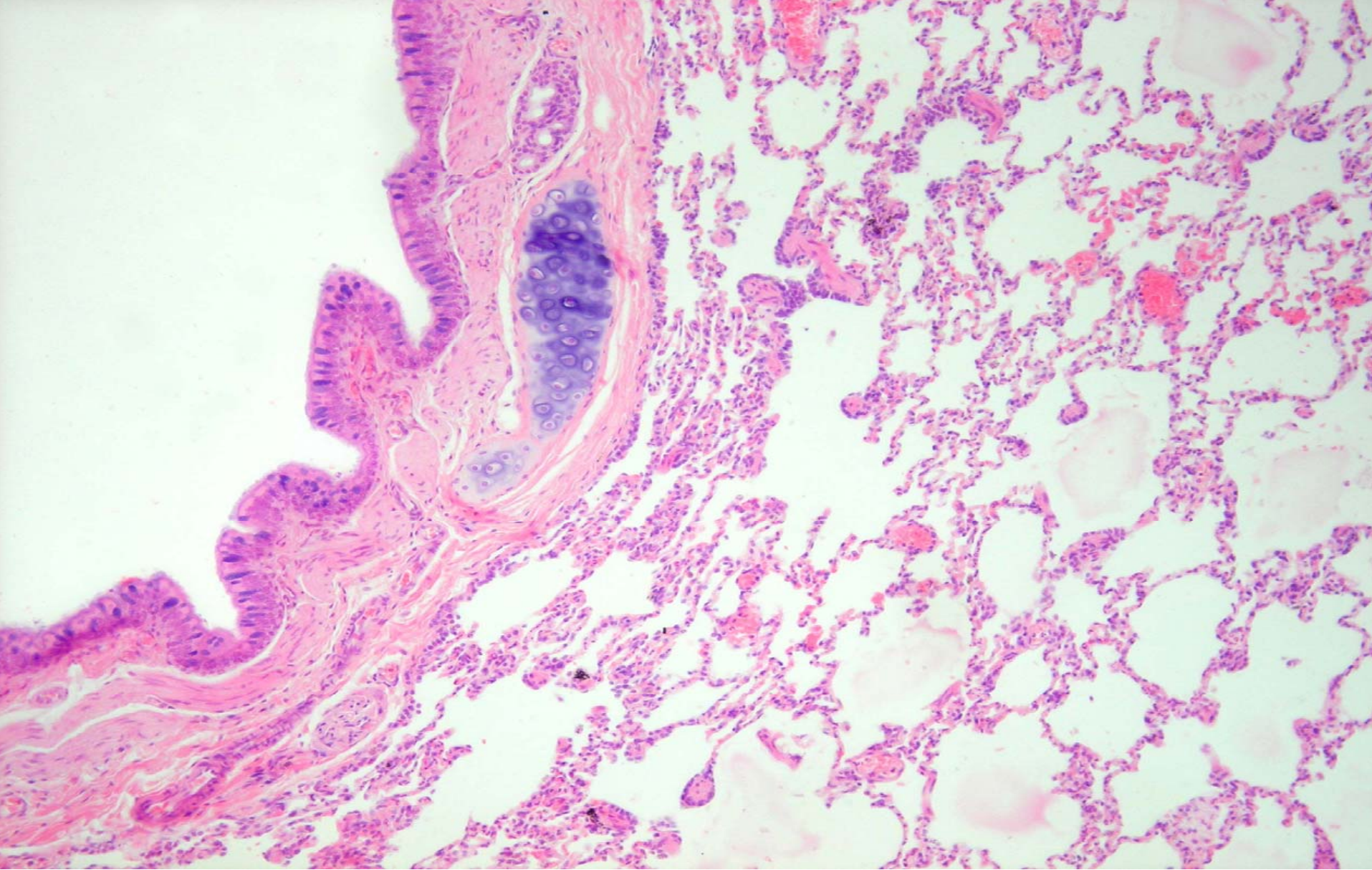
lung





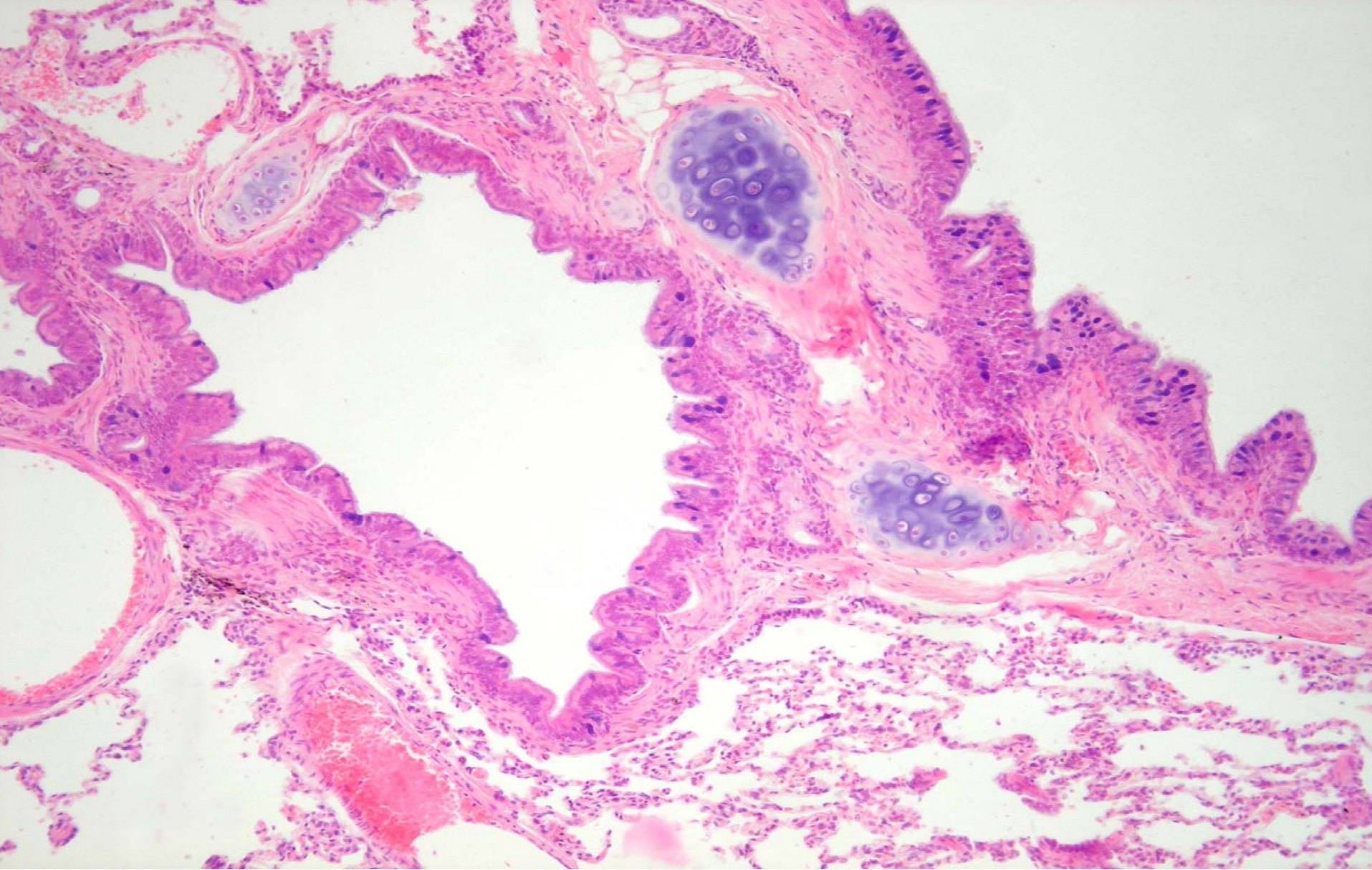
Small bronchi, bronchiole, terminal bronchiole





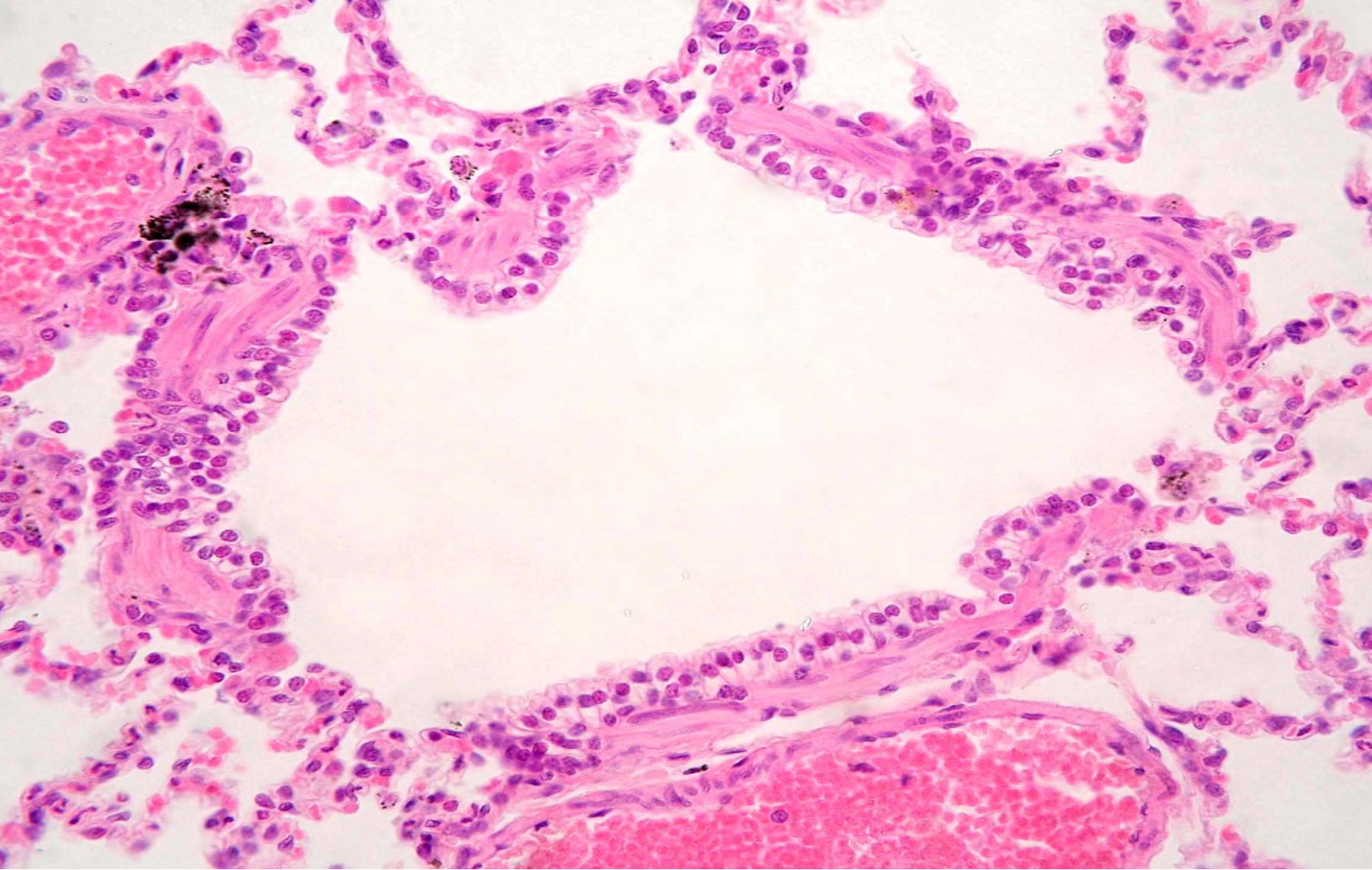
Small bronchi



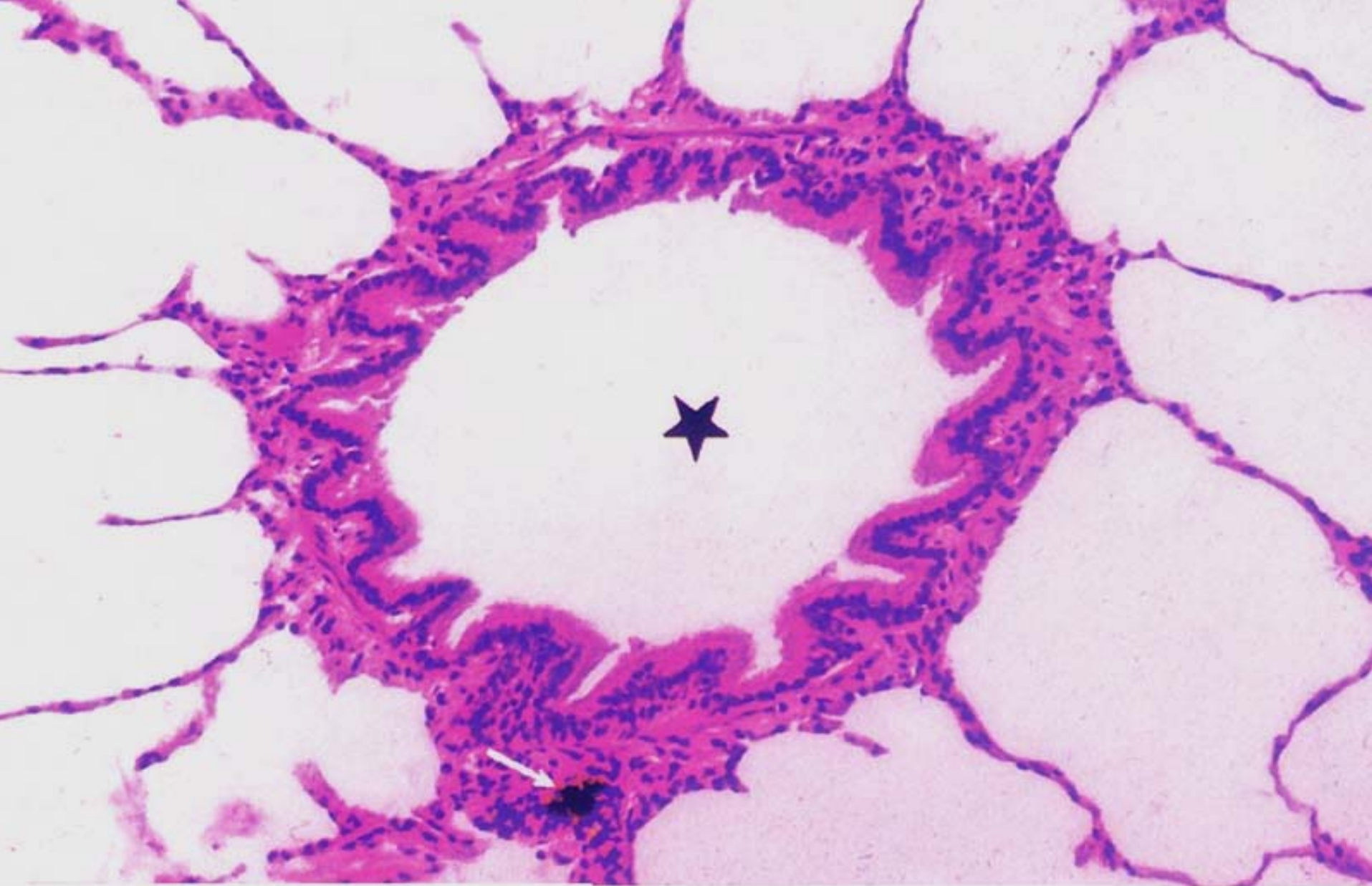


bronchiole



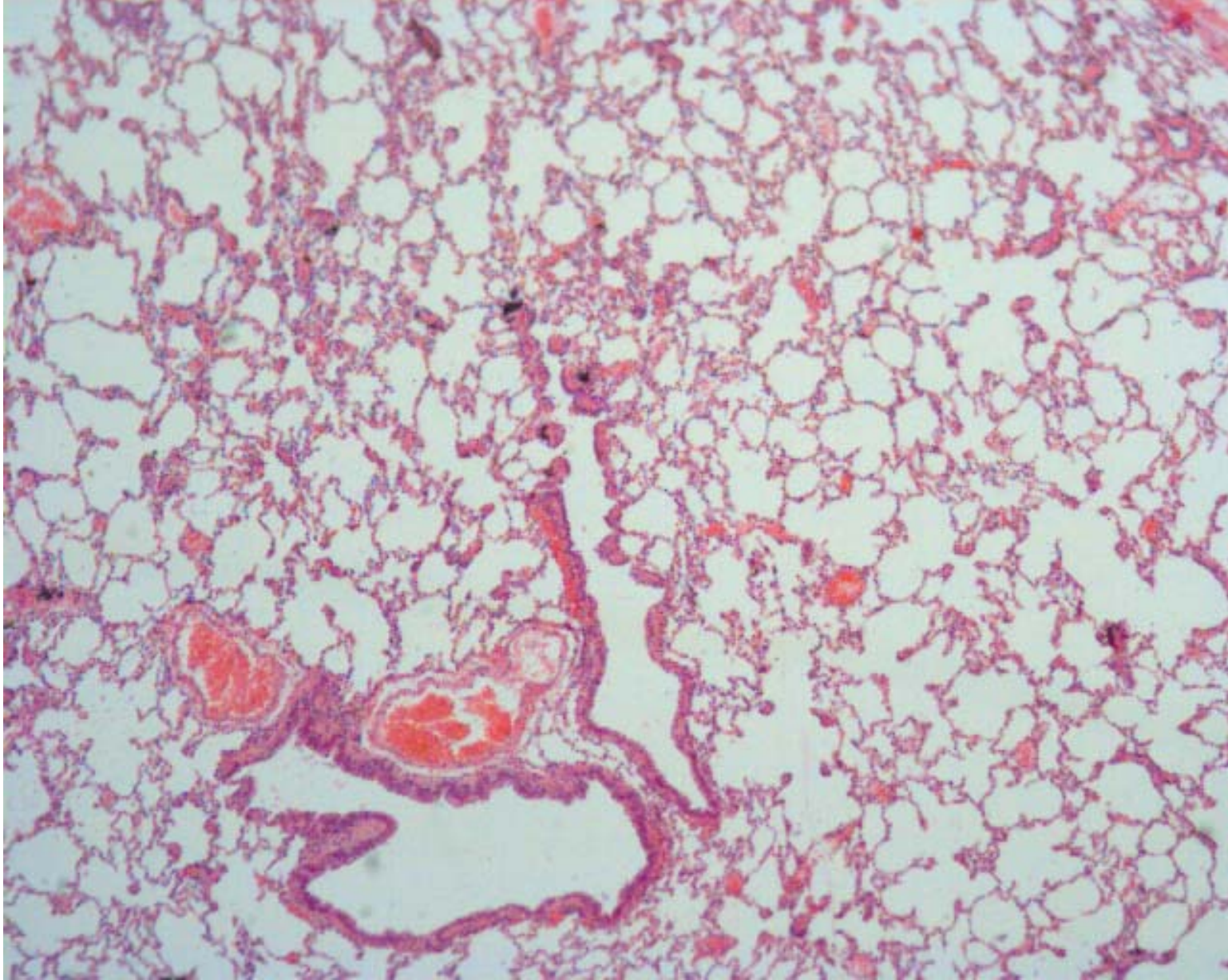


terminal bronchiole



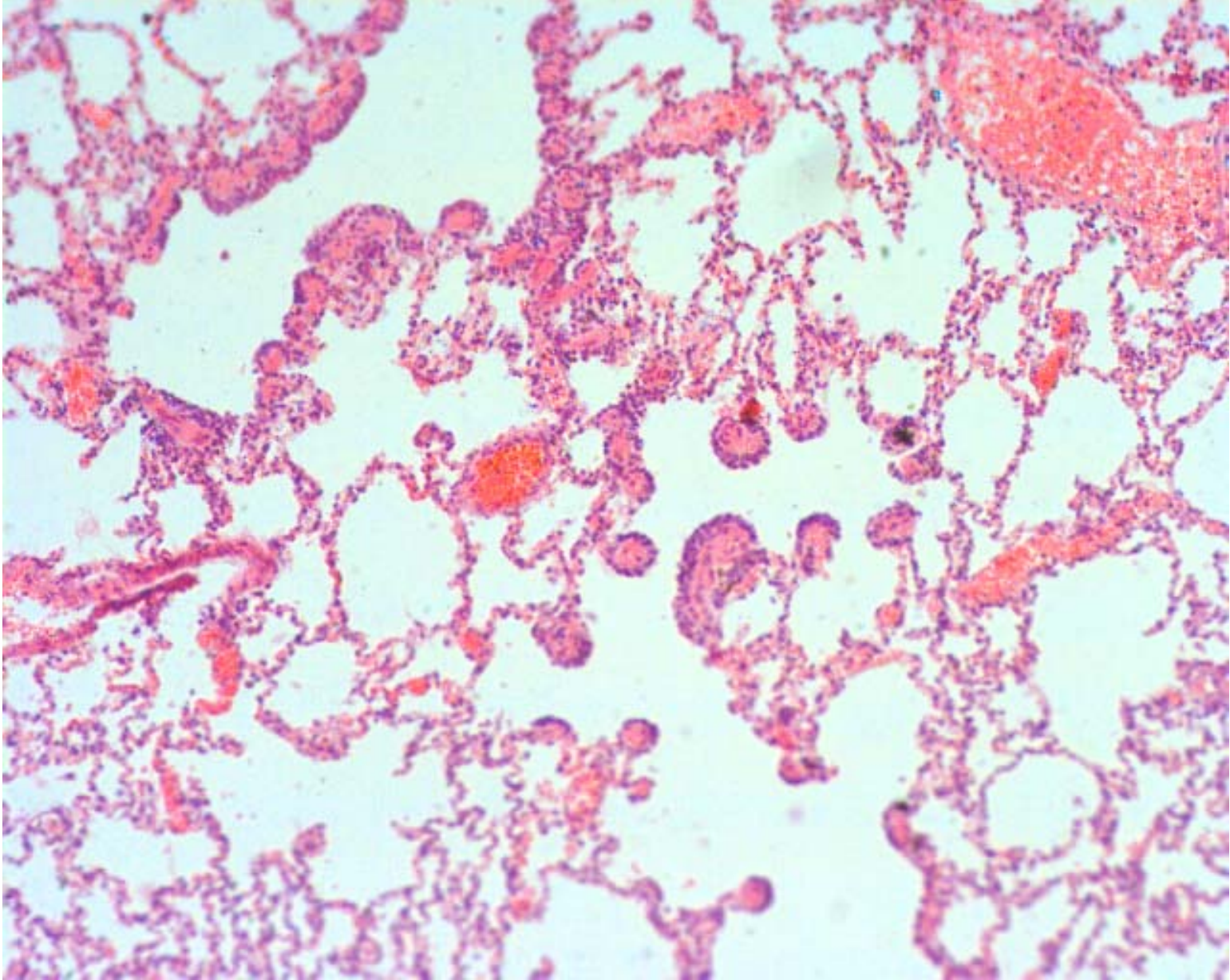
terminal bronchiole





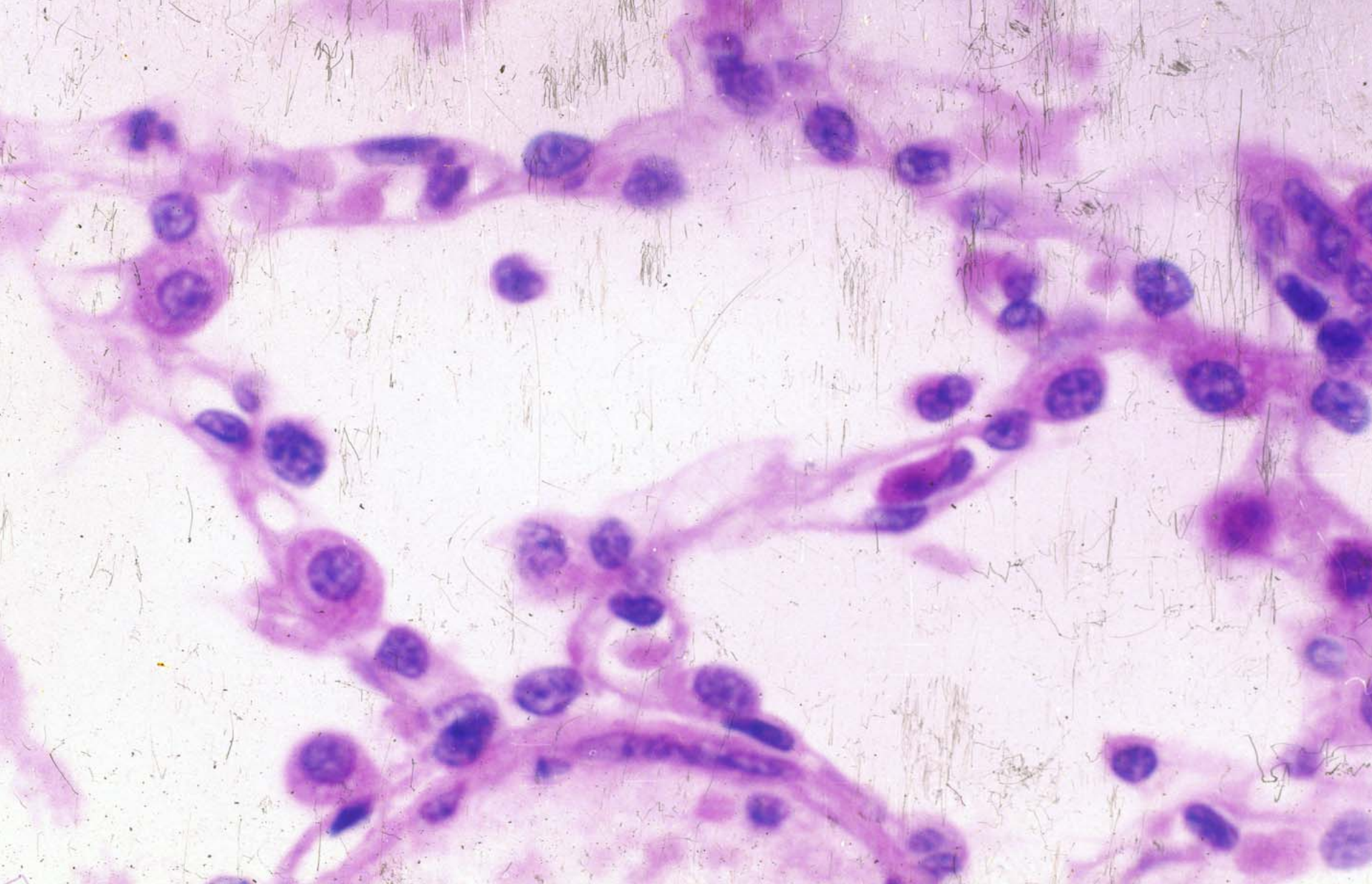
terminal bronchiole and respiratory bronchiole





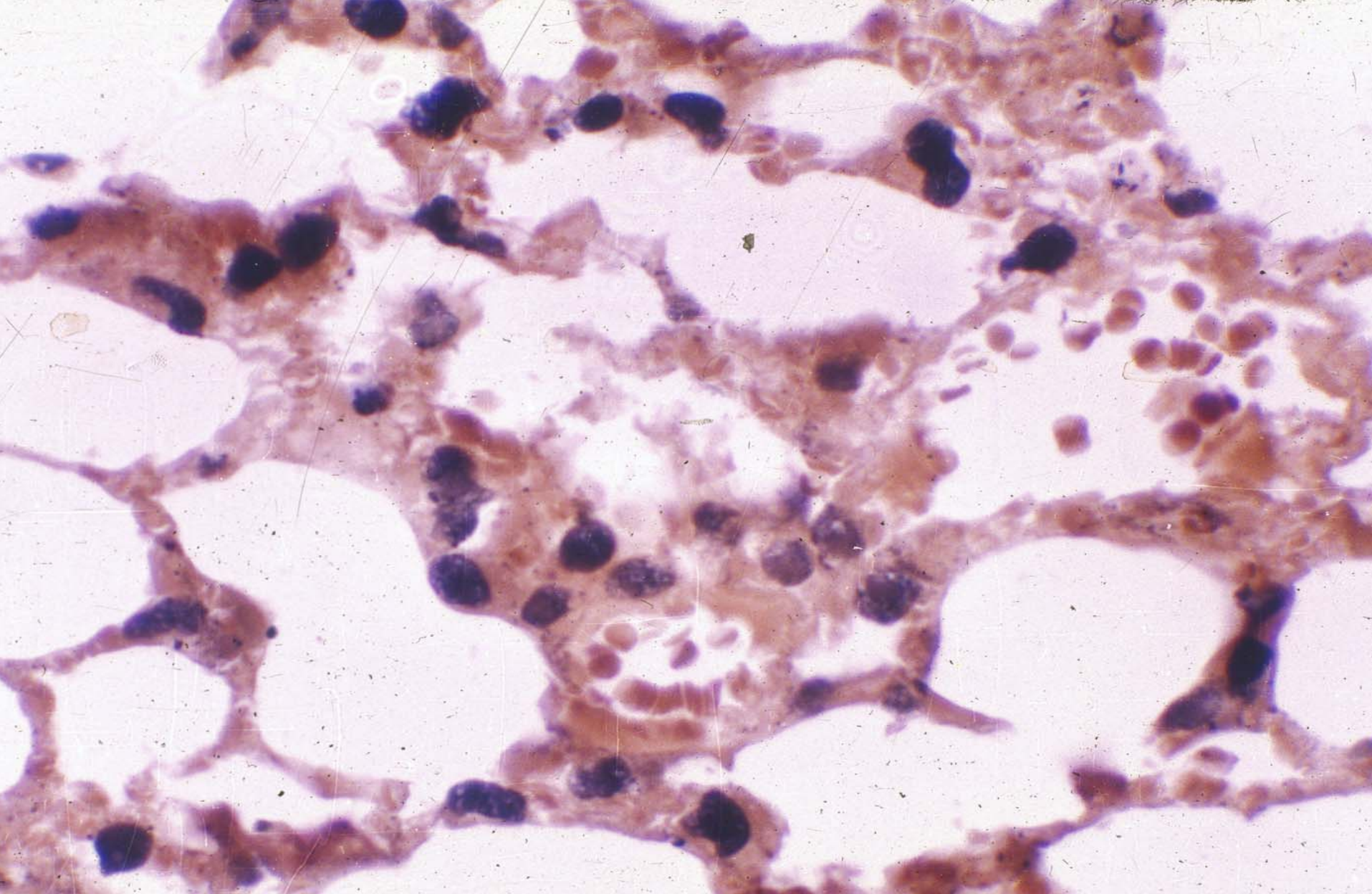
respiratory bronchiole, alveolar duct and alveolar sac





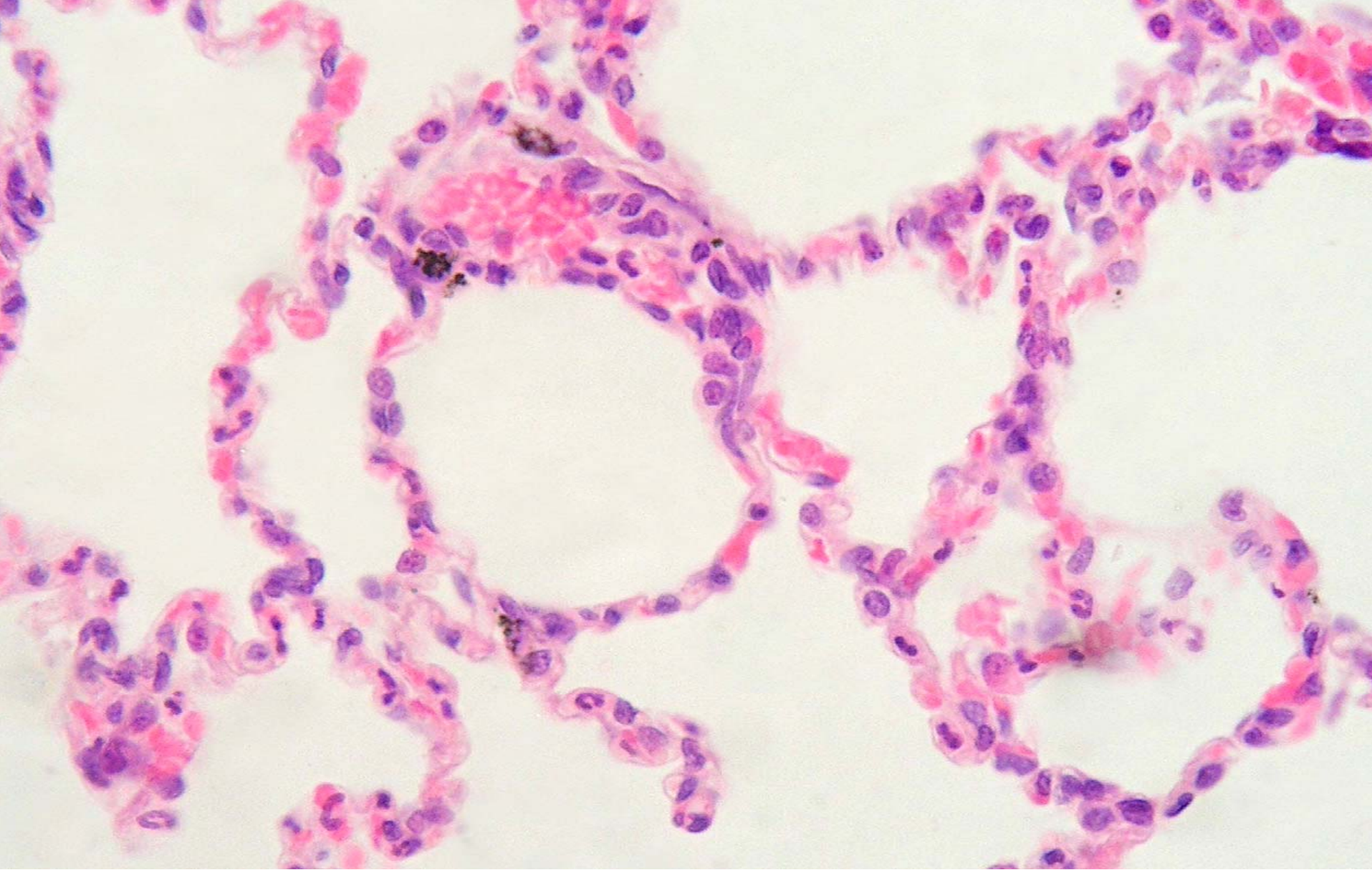
Pulmonary alveoli





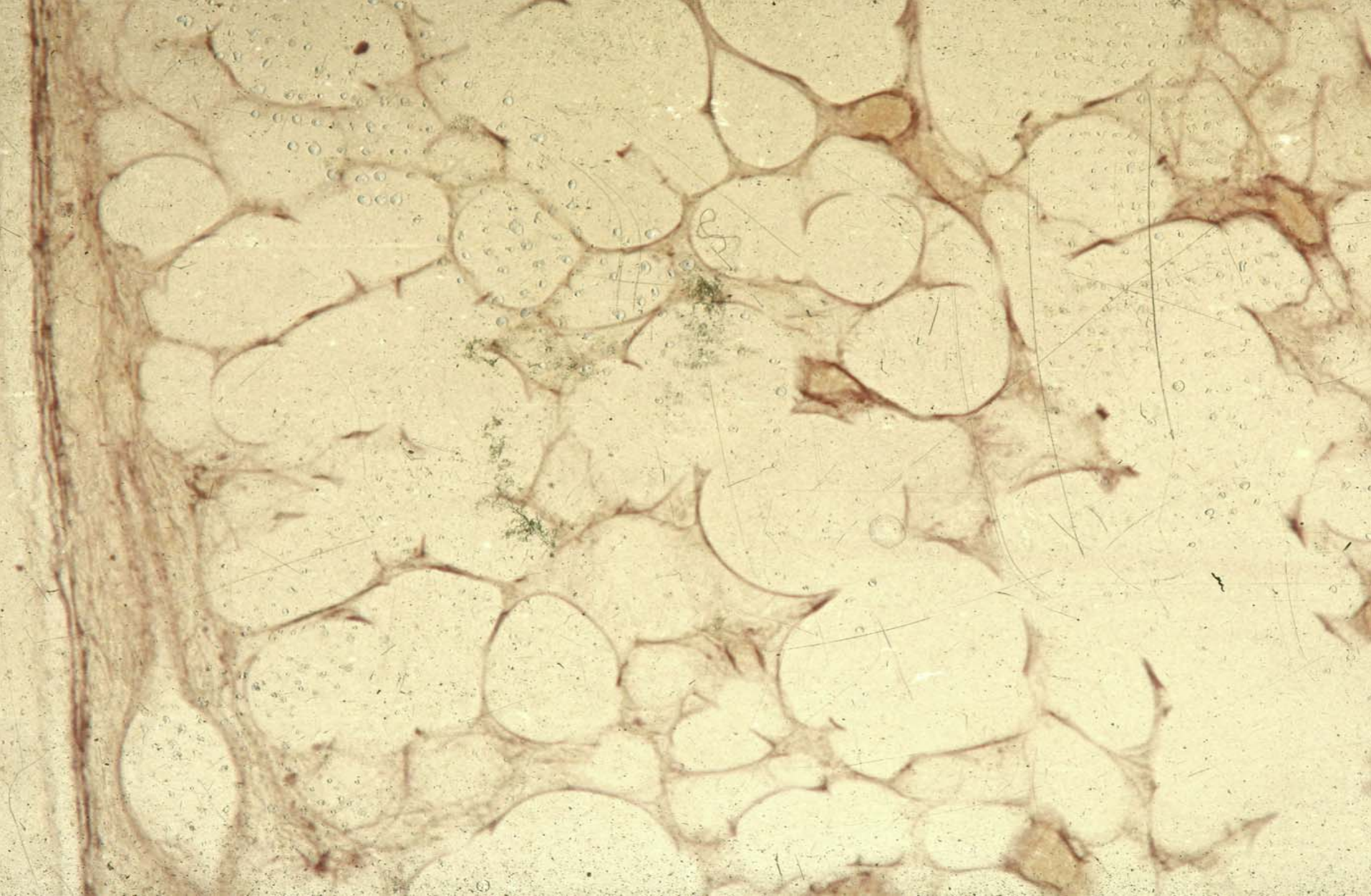
Type II alveolar cell





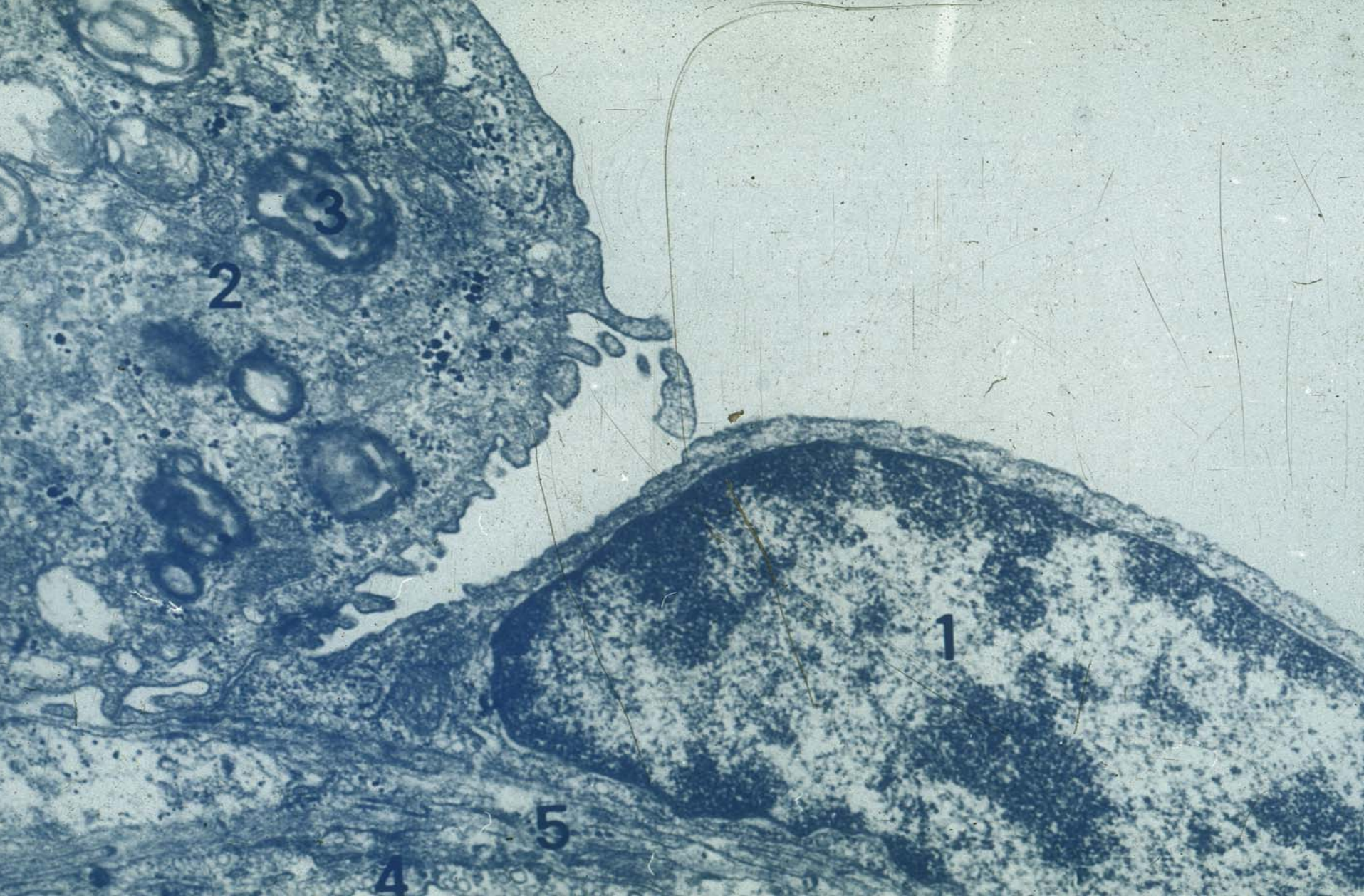
Dust cell





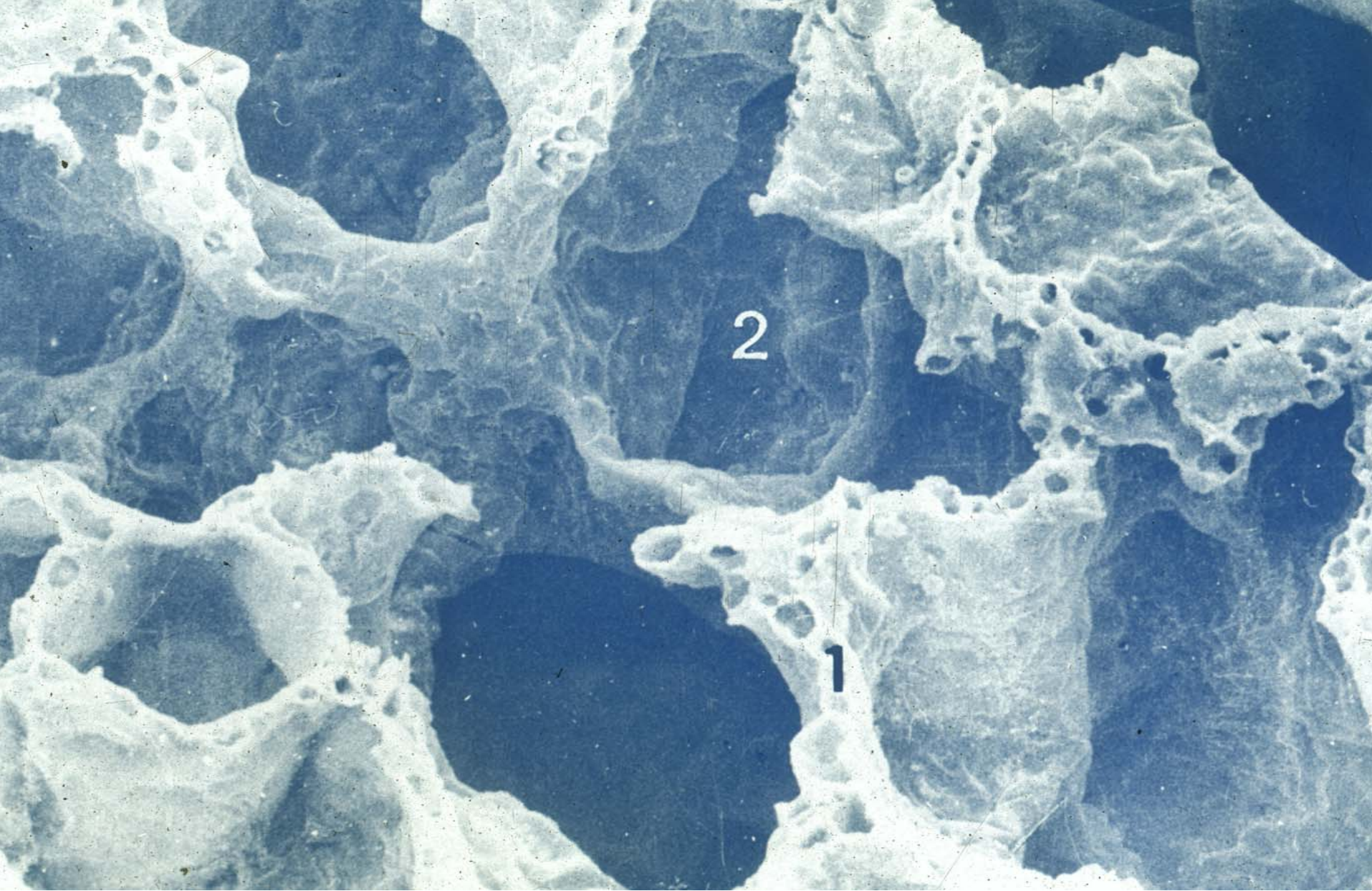
Elastic fiber





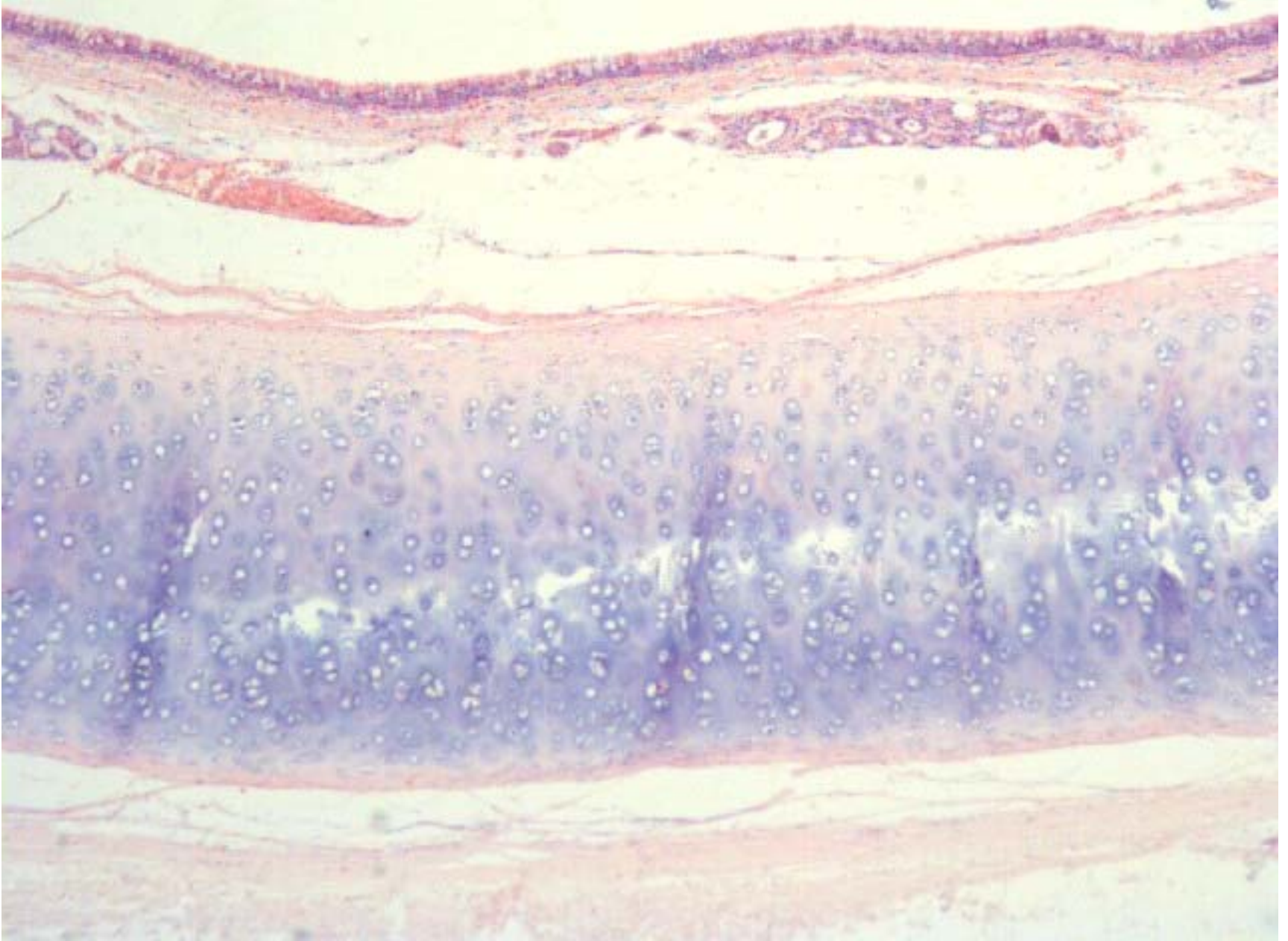
Blood-air barrier



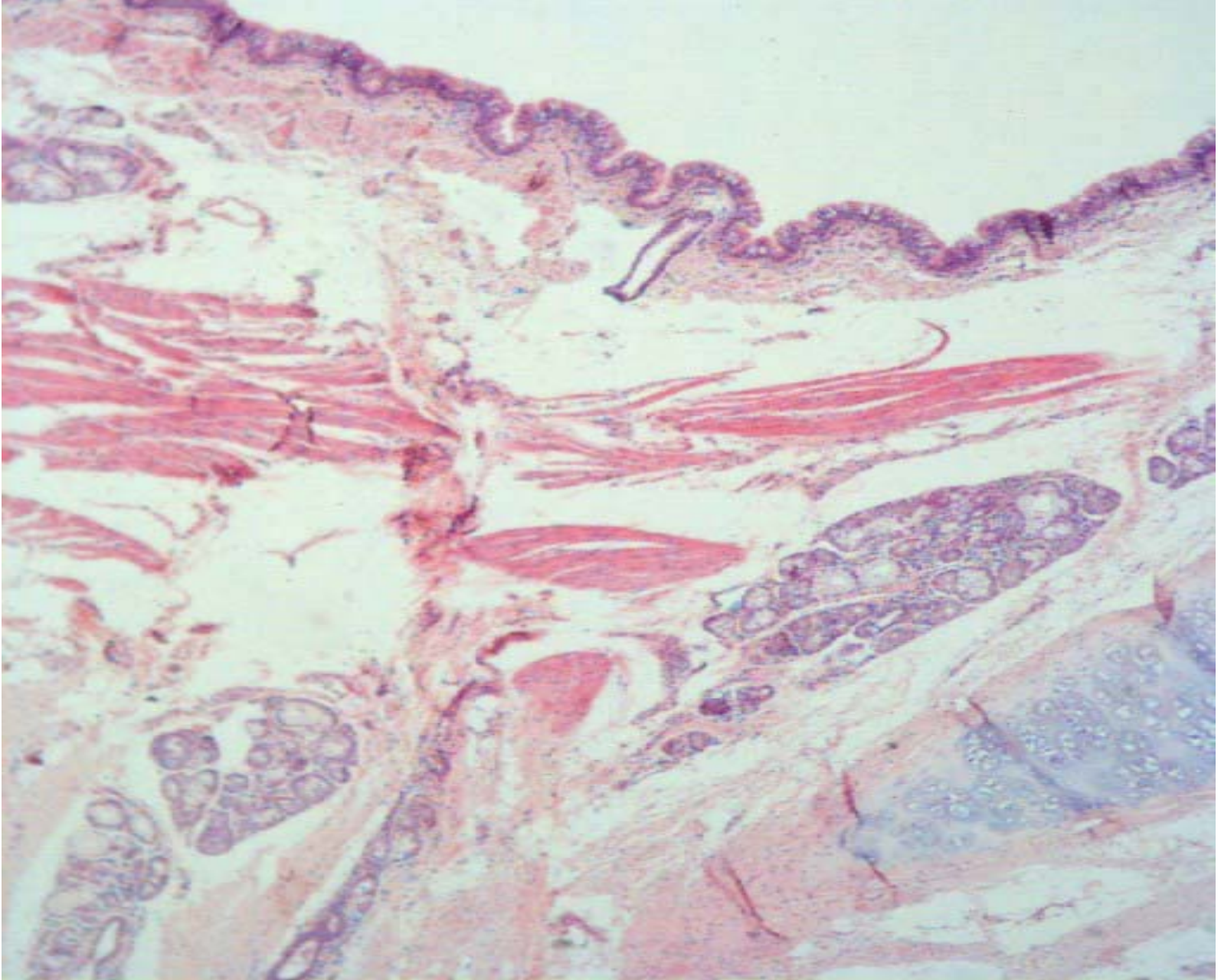


SEM of alveoli



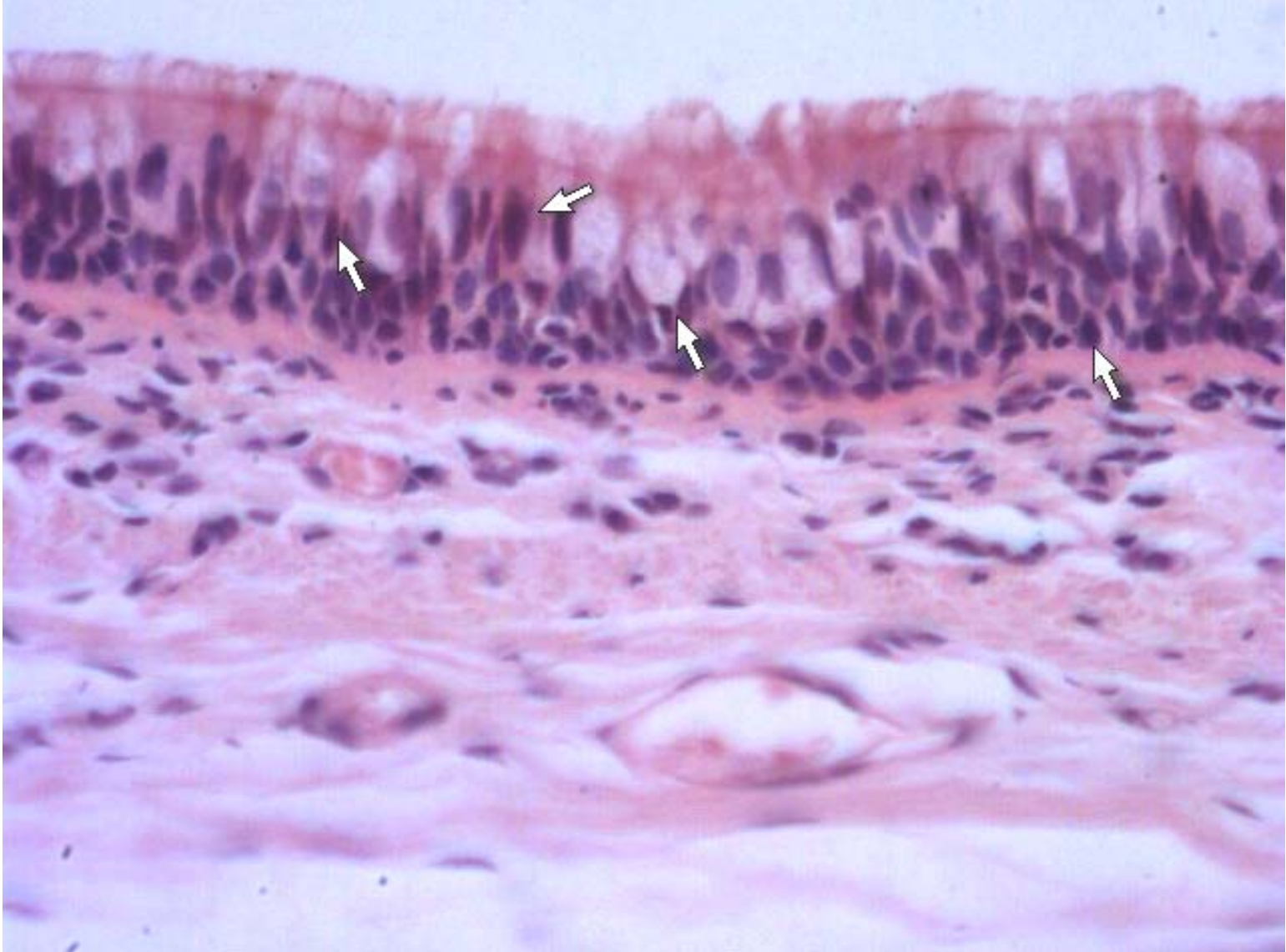


trachea

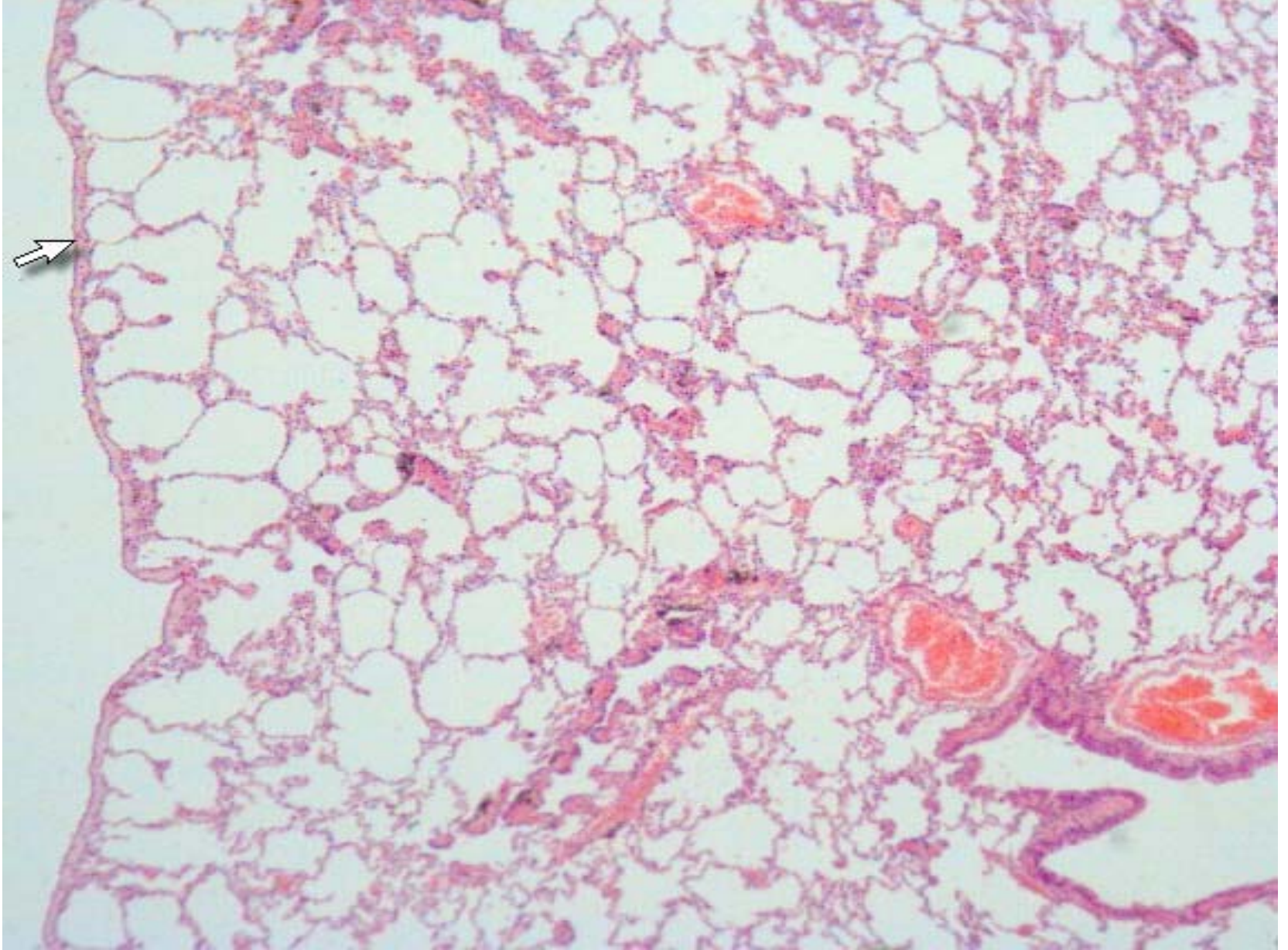


trachea



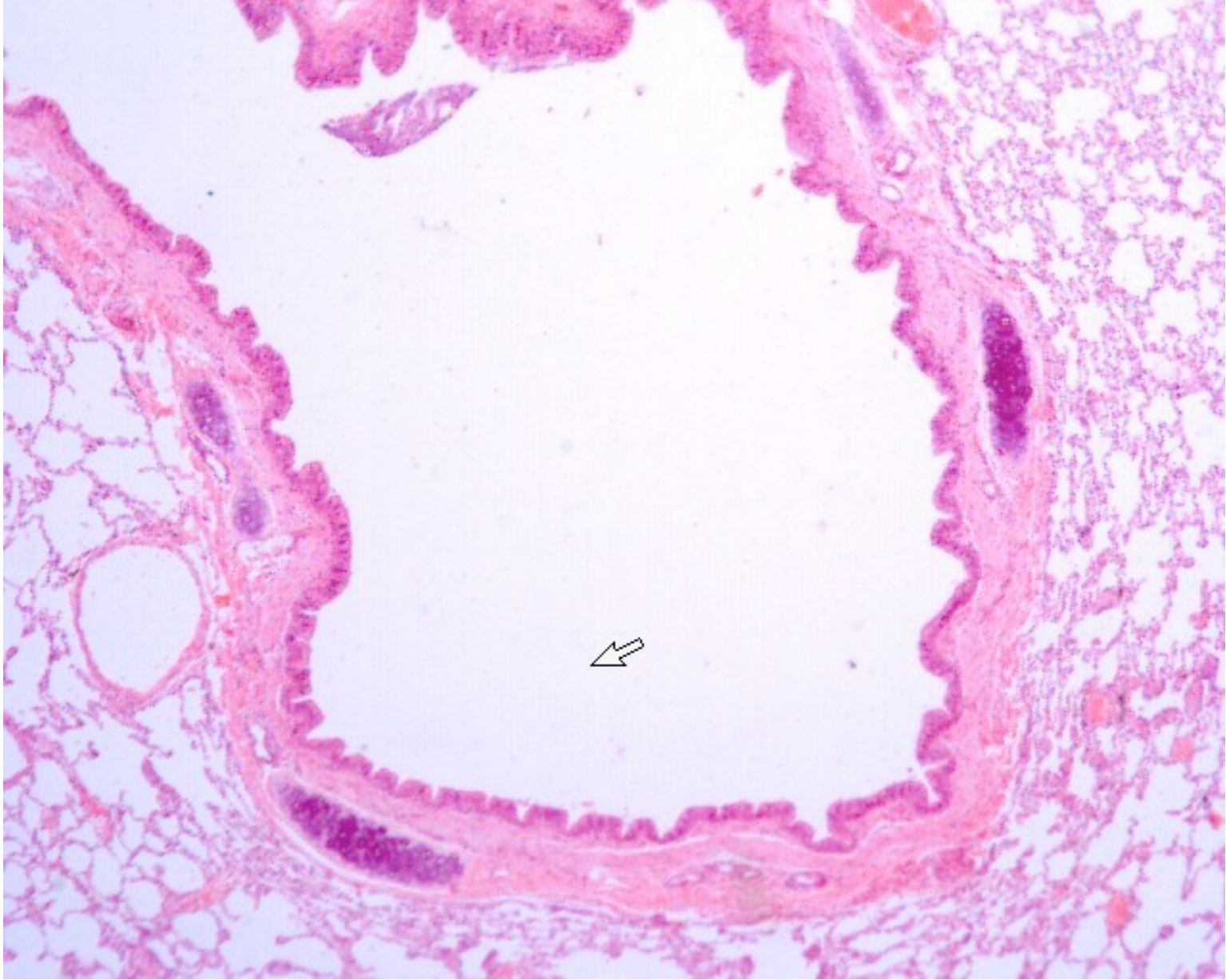


Pseudostriated ciliated columnar epithelium

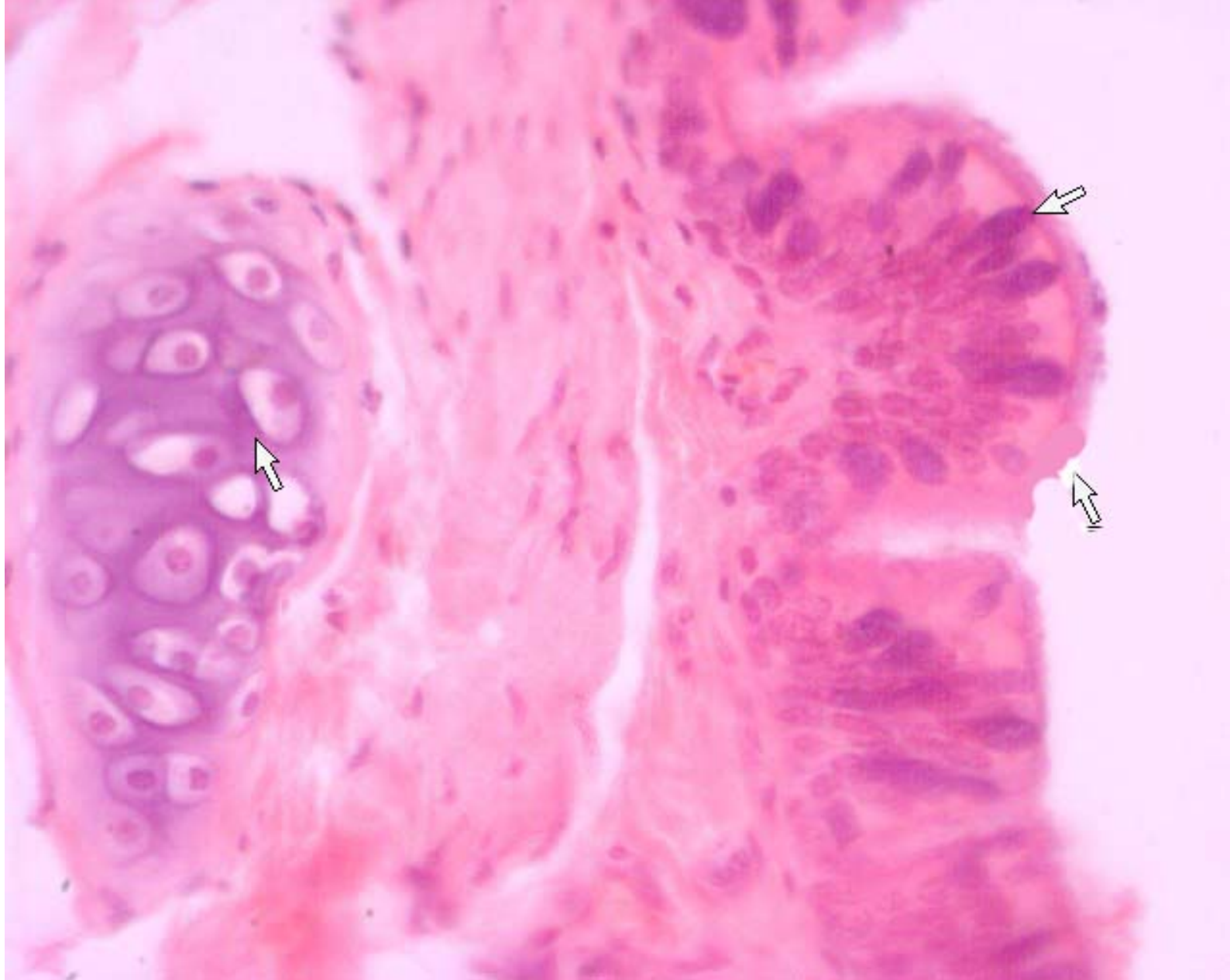


lung



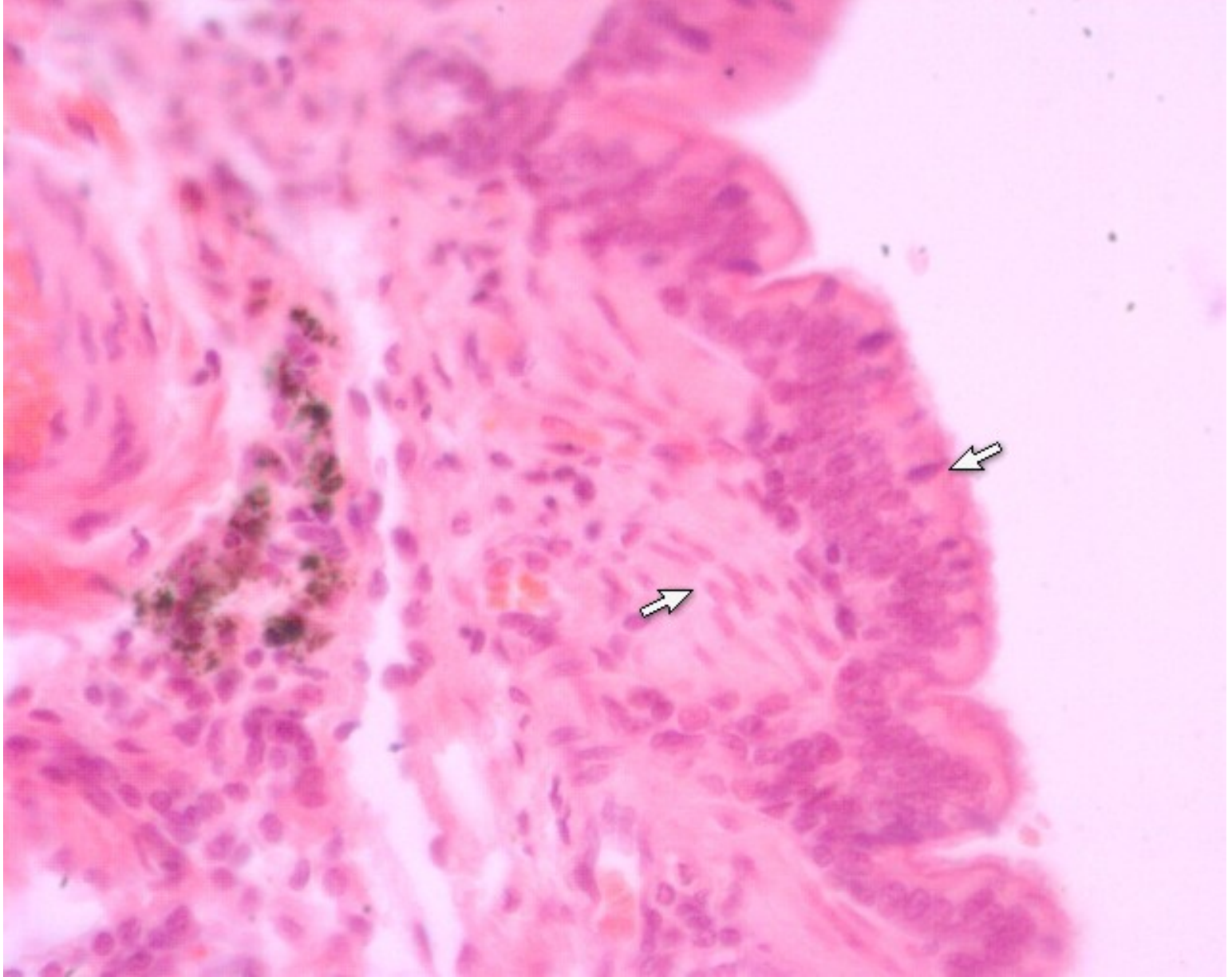


Small bronchi

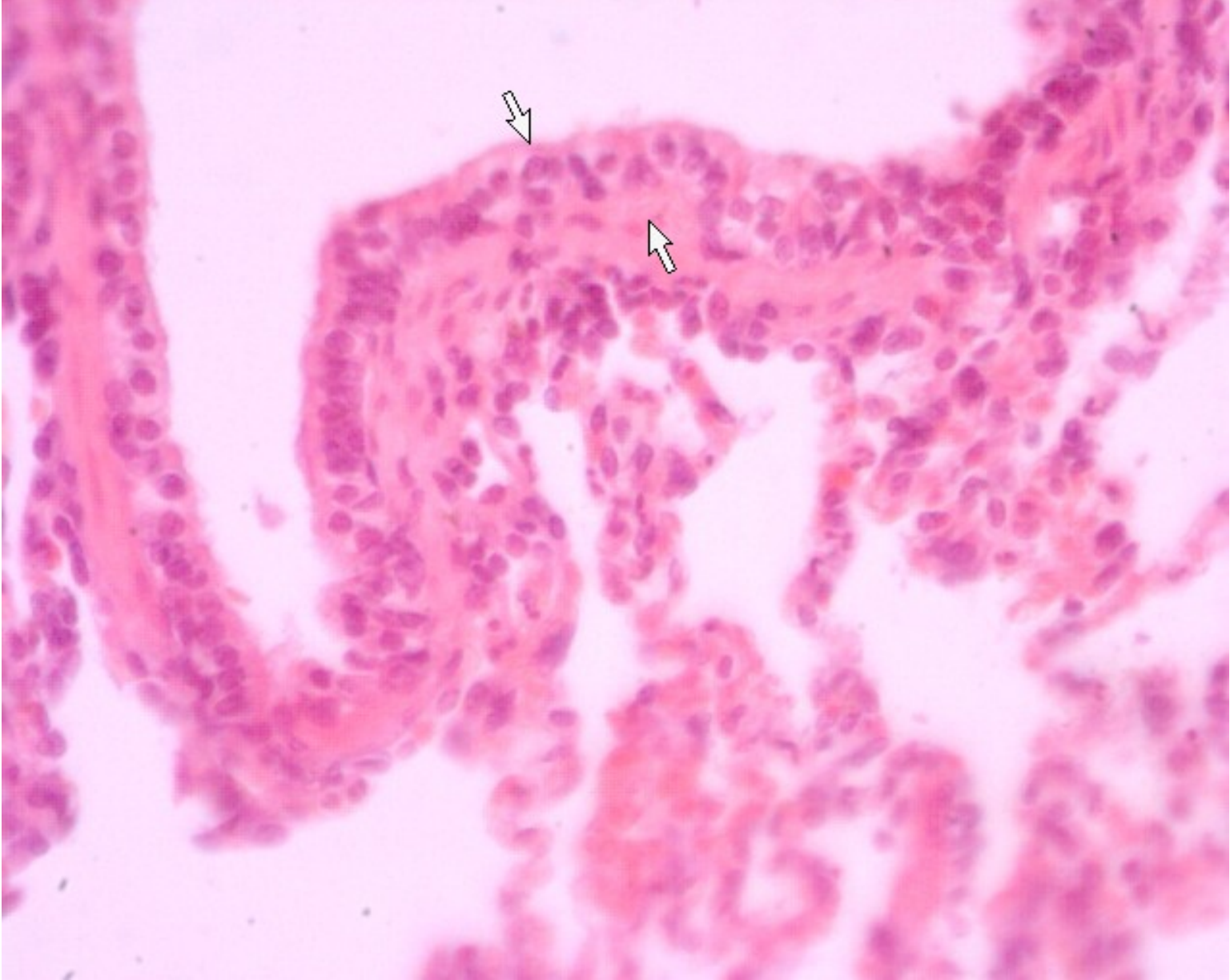


Small bronchi



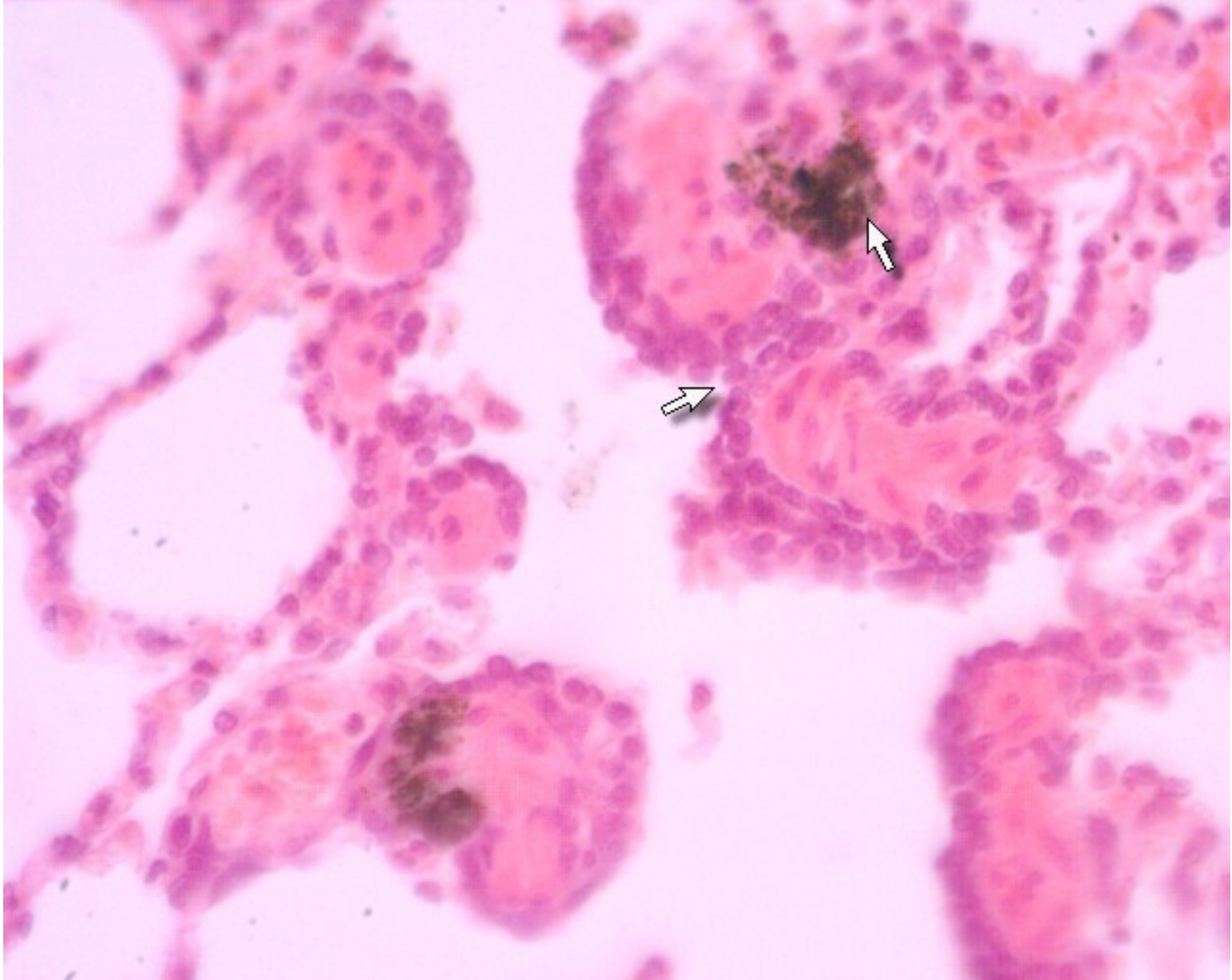


Small bronchi

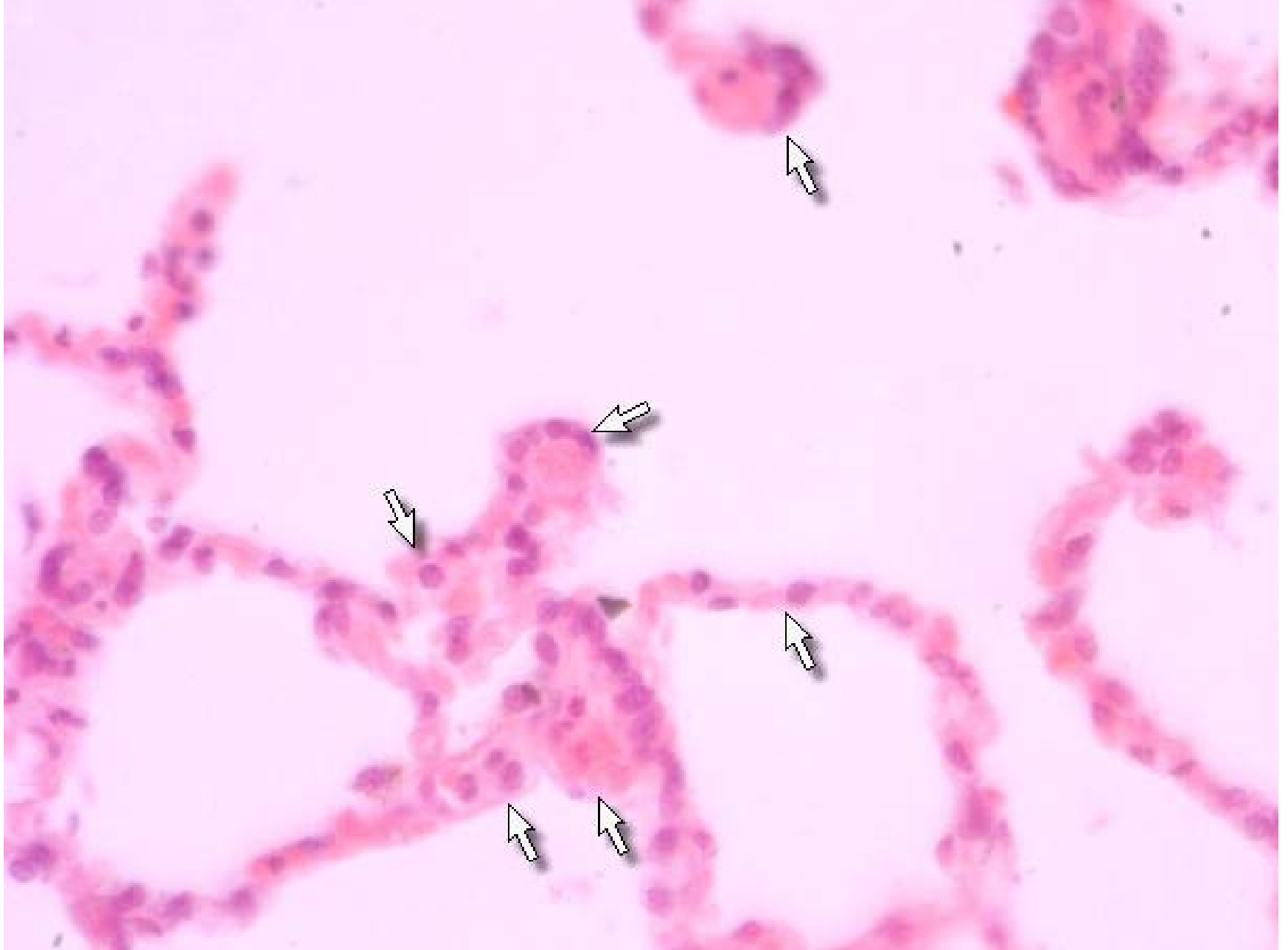

Terminal bronchiole





Alveolar duct and dust cell



Alveolar sac